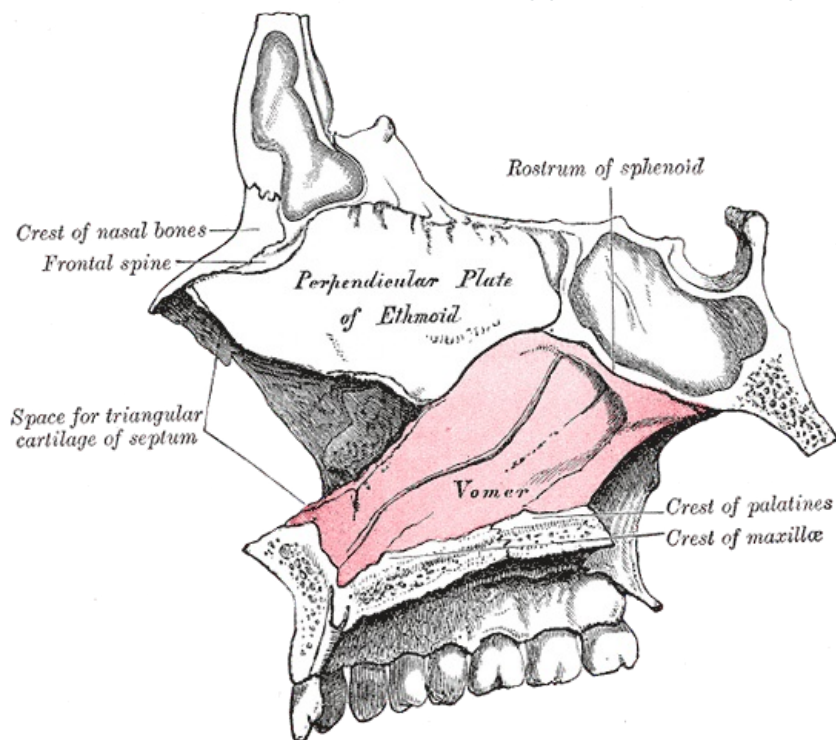


# Vomer

The *sword bone* is a small flat bone forming part of the nasal septum.



## Anatomical Structures

The sagittally positioned bone forms the dorsocaudal part of the nasal septum. Using the wing-like lamellae of the *alae vomeris*, it mounts to the rostrum and body sphenoid bone. It connects caudally to the *crista nasalis* *hard palate in the midline*. The scapula has a ventrocranial connection with the lamina perpendicularis ossis ethmoidalis.

## Most common variations

Thanks to the deviation of the nasal septum, the vomer is also deviated, almost always. Other variations may arise due to incomplete ossification.

## Links

### Related Articles

- Bones of the neurocranium
- Nasal cavity

### References

- ČIHÁK, Radomír. *Anatomie I*. 2. edition. Grada, 2001. 516 pp. pp. 162. ISBN 978-80-7169-970-5.

Template:Navbox - bones