

Varicocele

A **varicocele** (varicose veins of the scrotum) is created by dilated and twisted, varicosely altered veins of the plexus pampiniformis testis. Backflow of blood in the internal spermatic veins causes damage to the function of the testis and epididymis and atrophy of the testis, which is the most common cause of male infertility. Varicocele most often develops during puberty, but can occur at any time during a man's life. Varicocele is most often a bilateral disease. If left untreated, the degree of testicular damage increases.

Etiopathogenesis

Varicocele appears more often on the left side as a result of an anatomical predisposition – the exit of *the vena spermatica interna sinistra* into *the vena renalis sinistra*, when the veins form a right angle with each other. Varicocele leads to hyperthermia of the scrotum and thus to a reduction in the density of Leydig cells and hypofunction of Sertoli cells. Stagnation of blood in the microcirculation can cause local hypoxia and ischemia, can lead to an increase in vascular permeability and also to a decrease in arterial inflow.

Clinical picture

- subclinical: not clinically apparent, but can be demonstrated by Doppler ultrasonography and thermometry or thermography;
- symptomatic: orchialgia, scrotal discomfort;
- infertility: abnormal spermiogram, azoospermia.

Diagnostics

- Doppler ultrasonography (venous valvular incompetence) + thermography or thermometry (thermoregulation disorder).

Therapy

- interruption of venous reflux by surgery or retrograde transcatheter embolization – leads to an improvement in sperm quality.

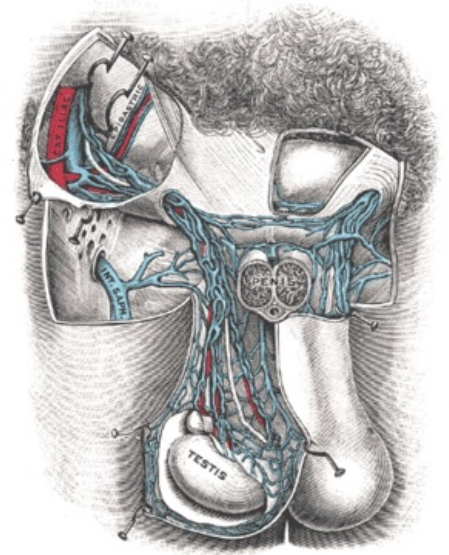
Links

Related Articles

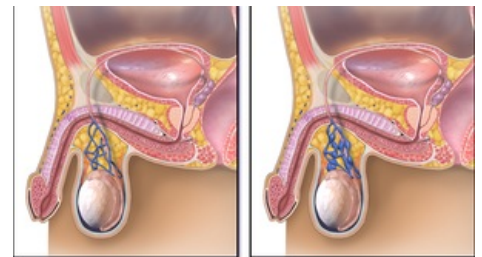
- Hydrocele

References

- KUBÍČEK, Vladimír. Varicocele, a disorder of the venous drainage of the testicles. *Urology for practice* [online]. 2010, vol. 1, p. 11-21, Available from <<https://www.urologiepropraxi.cz/pdfs/uro/2010/01/03.pdf>>.



Plexus pampiniformis



Normal

Varicocele

Varicocele