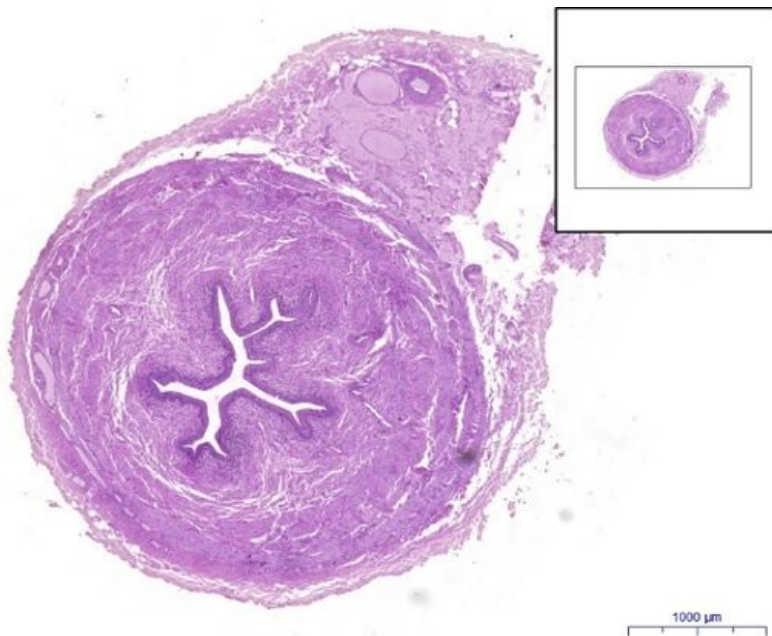


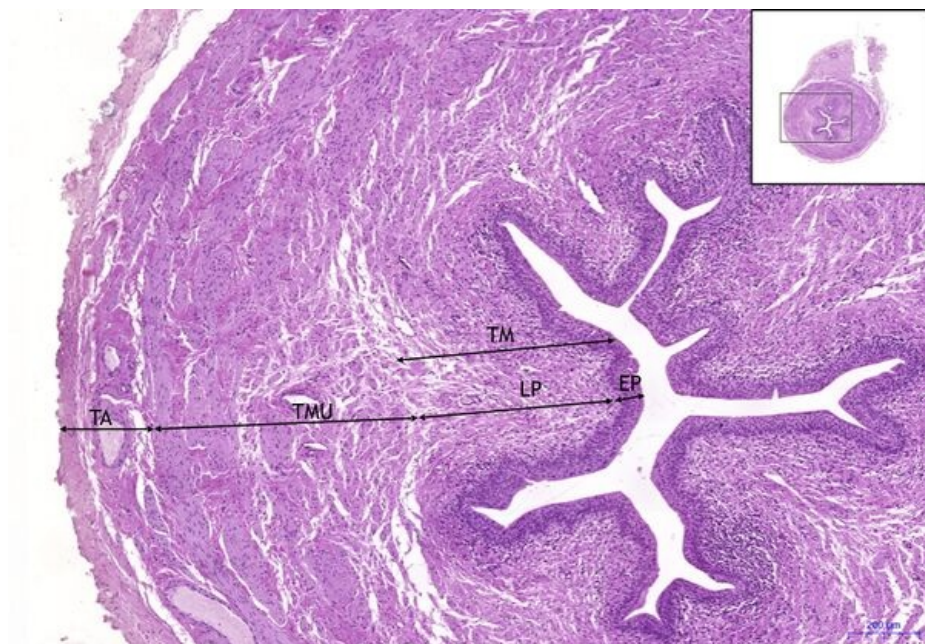
# Ureter - HE

## Ureter HE, 1,6x



**Ureter:**

## Ureter HE, 5x



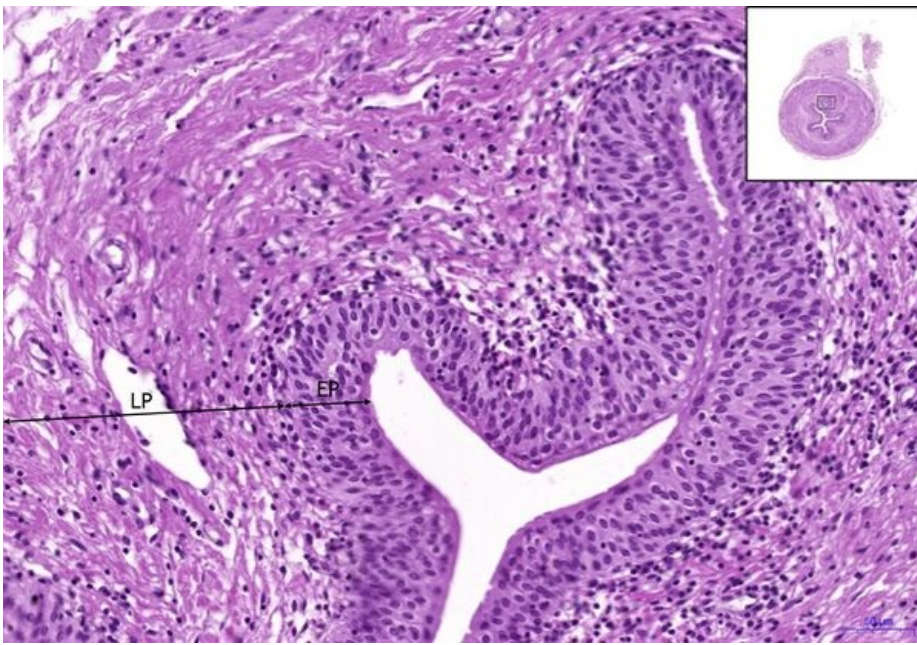
**Ureter:**

- 1) TM** - tunica mucosa
- a) EP** - transitional epithelium (urothelium)
- b) LP** - lamina propria
- 2) TMU** - tunica muscularis
- 3) TA** - tunica adventitia

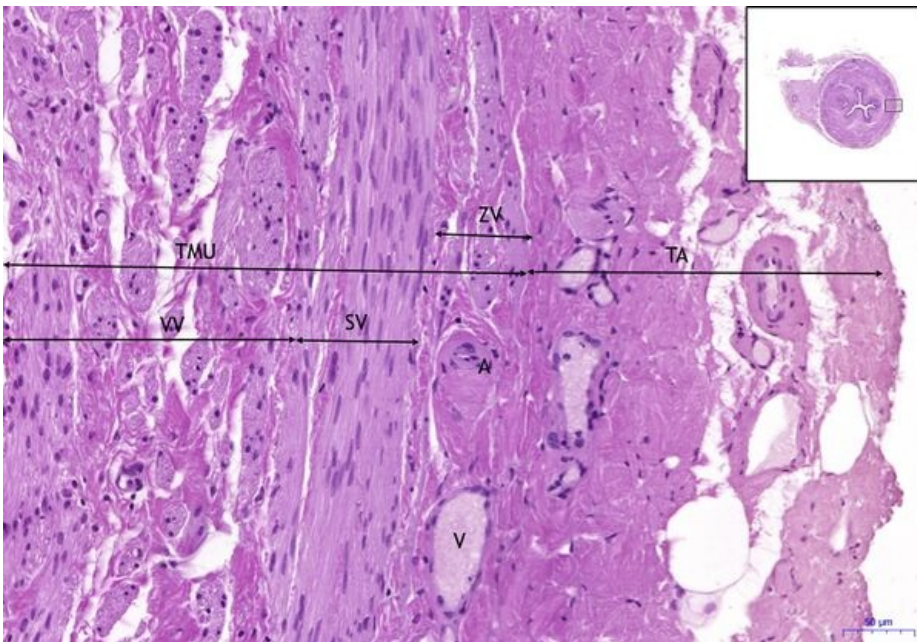
## Ureter HE, 10x

**Ureter:**

- 1) TM** - tunica mucosa
- a) EP** - transitional epithelium (urothelium)
- b) LP** - lamina propria



## Ureter HE, 10x (2)



### Ureter:

- 2) TMU** – tunica muscularis  
**a) VV** – inner layer  
**b) SV** – medium layer  
**c) ZV** – outer layer

- 3) TA** – tunica adventitia  
**a) A** – artery  
**b) V** – vein

## Navigation

### Navigation: Urinary system

← Slide U2 | List of the slides | Slide U4 →