

Upper limb muscles

The muscles of the upper limb include the following muscle groups:

Shoulder and scapular muscles

- Musculus deltoideus
- Musculus supraspinatus
- Musculus infraspinatus
- Musculus teres minor
- Musculus teres major
- Musculus subscapularis

Arm muscles

Anterior group

- Musculus biceps brachii
- Musculus coracobrachialis
- Musculus brachialis

Posterior group

- Musculus Triceps brachii
- Musculus anconeus

The **Septa** go from the periosteum to the superficial fascia of the arm and create the **osteofascial spaces**:

- **Septum intermusculare brachii mediale** - goes from the tendon of the latissimus dorsi and teres major muscles to the medial epicondyle of the humerus;
- **Septum intermusculare brachii laterale** - goes from the attachment of the deltoideus muscle to the lateral epicondyle.

Forearm muscles

Anterior group

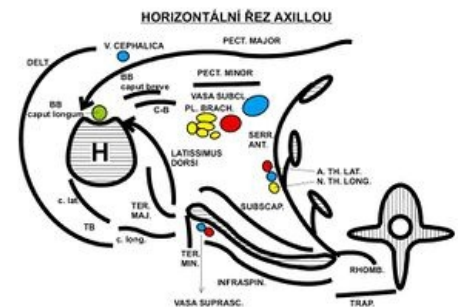- surface layer
 - Musculus pronator teres
 - Musculus flexor carpi radialis
 - Musculus palmaris longus
 - Musculus flexor carpi ulnaris
- second layer
 - Musculus flexor digitorum superficialis
- third layer
 - Musculus flexor digitorum profundus
 - Musculus flexor pollicis longus
- fourth, deep layer
 - Musculus pronator quadratus

Lateral group

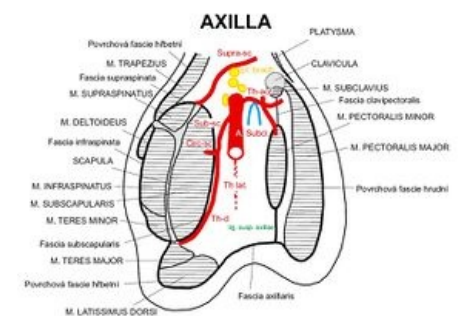
- surface layer
 - Musculus brachioradialis
 - Musculus extensor carpi radialis longus
 - Musculus extensor carpi radialis brevis
- deep layer
 - Musculus supinator

Dorsal group of forearm muscles

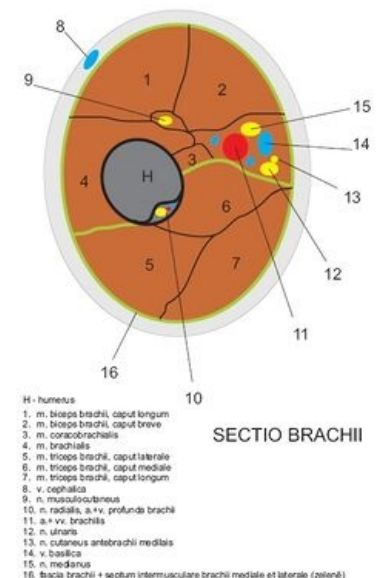
- surface layer
 - Musculus extensor digitorum
 - Musculus extensor digiti minimi
 - Musculus extensor carpi ulnaris



Horizontal section of the axilla



Sagittal section of the axilla



Cross section of arm

- deep layer
 - Musculus abductor pollicis longus
 - Musculus extensor pollicis brevis
 - Musculus extensor pollicis longus
 - Musculus extensor indicis

Hand muscles

Thumb - *thenar* group

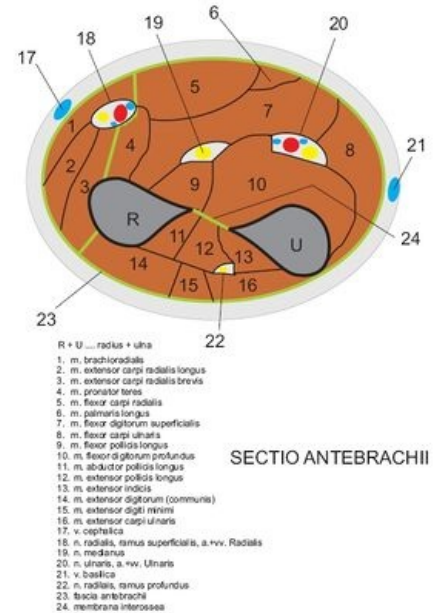
- Musculus abductor pollicis brevis
- Musculus flexor pollicis brevis
- Musculus opponens pollicis
- Musculus adductor pollicis

Little finger - *hypothelar* group

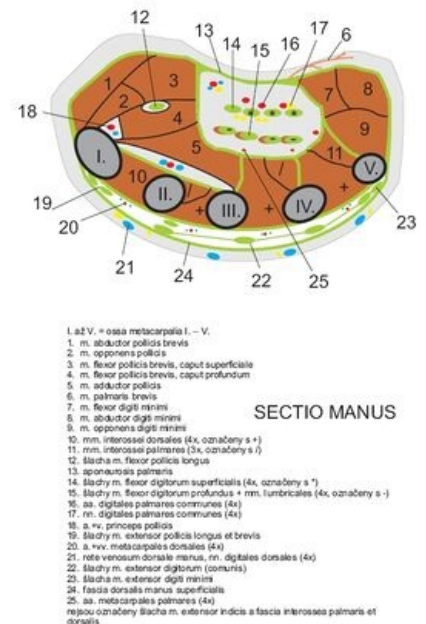
- Musculus palmaris brevis
- Musculus abductor digiti minimi (hand)
- Musculus flexor digiti minimi brevis (hand)
- Musculus opponens digiti minimi (hand)

Muscles of the middle space

- Musculi lumbricales manus
- Musculi interossei manus
 - Musculi interossei palmares I-III
 - Musculi interossei dorsales I-IV



Cross section of forearm



Cross section of hand