

Tumors of the heart

- **Primary heart tumors** are relatively rare.
- **Secondary heart tumors** are much more common, affecting up to 20% of patients dying from generalized cancer.^[1]

Division of the tumors

We distinguish tumors:

1. **primary**;
 1. **benign** (myxoma, fibroma, neurofibroma, lipoma, hemangioma, lymphangioma, rhabdomyoma, teratoma);
 2. **malignant** (angiosarcoma, fibrosarcoma, rhabdomyosarcoma, malignant mesothelioma);
2. **secondary** (metastases – malignant tumors of the breast, lungs, etc.).

⚠ **Even benign tumors can cause serious hemodynamic deficit!**

Primary heart tumors

Primary heart tumors are significantly less common than secondary tumors.

Benign tumors

Benign heart tumors include:

Papillary fibroelastoma

A warty or tuft-like formation on the heart valves.

Myxoma of the heart

In 80% of cases it is located in the left atrium, in 15% in the right atrium, in 5% in the left or right ventricle.

Clinical symptoms

- in case of embolization: ischemia of the organs supplied by the embolized artery;
- in case of obstruction of the mitral orifice: shortness of breath, increased fatigue, cough, hemoptysis, pulmonary edema;
- in case of obstruction of the tricuspid orifice: symptoms of right-sided heart failure

Cardiac myxoma can be accompanied by a number of non-specific symptoms.

Diagnostics

- Anamnesis.
- Physical exam.
- **Echocardiography.**

Therapy

- surgical removal,
- echocardiographic monitoring.

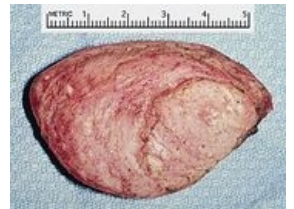Carney syndrome

= **complex myxoma syndrome.**

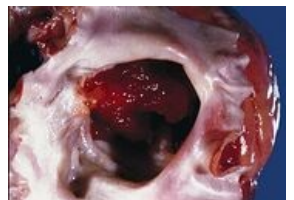- This is a rare syndrome in which cardiac myxoma is associated with:
 - multiple pigment nevi,
 - adrenocortical hyperplasia,
 - pituitary tumors,
 - multiple breast fibroadenomas,
 - Sertoli tumor of the testicles,
 - cutaneous myxomas

Rhabdomyoma

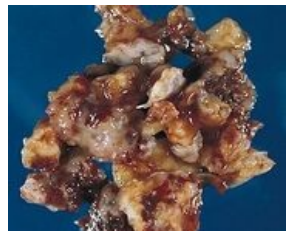See the *Rhabdomyoma* page for more detailed information.



Cardiac rhabdomyoma in the right ventricle in a three-year-old girl externally presenting with a heart murmur.



Cardiac myxoma: gelatinous tumor almost completely filling the left atrium.

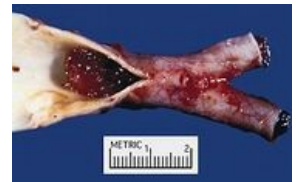


Cardiac myxoma: 71-year-old man hospitalized for TIA; transesophageal echocardiography showed cardiac myxoma in the left atrium.

Malign tumors

Sarcomas

- **Angiosarcoma, rhabdomyosarcoma** (fibrosarcoma, liposarcoma, osteosarcoma),
- occur at any age,
- most often in the right atrium,
- **clinically:** manifestations of heart failure, arrhythmia, pain in the precordium, pericardial effusion, cardiac tamponade, sudden cardiac death; embolization (of tumor masses, thrombi; often to the CNS), pulmonary edema, syncope (for tumors in the left atrium); extracardiac metastases (lungs, mediastinum, spine, etc.); prognosis very unfavorable (approx. 3 months),
- **diagnosis:** weight loss, club fingers, heart failure, arrhythmia, pericardial friction murmur, diastolic tip murmur / regurgitation systolic murmur; hl. ECHO, CT and MRI,
- **therapy:** surgical removal, but usually only palliative surgery.

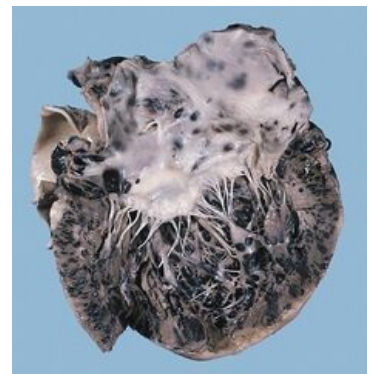


Cardiac myxoma embolus in aa bifurcation. iliacae communes

Secondary heart tumors

*This is a **metastatic involvement of the heart:***

- no tumor (with the exception of malignant melanoma) metastasizes exclusively to the heart,
- **heart metastases:** malignant melanoma, bronchogenic carcinoma, breast cancer,
- **clinically:** acute pericarditis, cardiac tamponade, rapid enlargement of the cardiac shadow, arrhythmia incl. atrioventricular blocks, rapid development of heart failure (however, 90% of metastases are clinically silent),
- **therapy:** hl. palliation: pericardiocentesis for effusion, radiotherapy, chemotherapy.



Malignant melanoma
metastasizing to the heart

Links

Related articles

- Tumors of the mediastinum

References

- KLENER, Pavel, et al. *Vnitřní lékařství*. 3. edition. Praha : Galén, 2006. 1158 pp. ISBN 80-7262-430-X.
 - VANĚK, Ivan, et al. *Kardiiovaskulární chirurgie*. 1. edition. Praha : Karolinum, 2003. 236 pp. ISBN 8024605236.
1. VANĚK, Ivan, et al. *Kardiiovaskulární chirurgie*. 1. edition. Praha : Karolinum, 2003. 236 pp. ISBN 8024605236.