

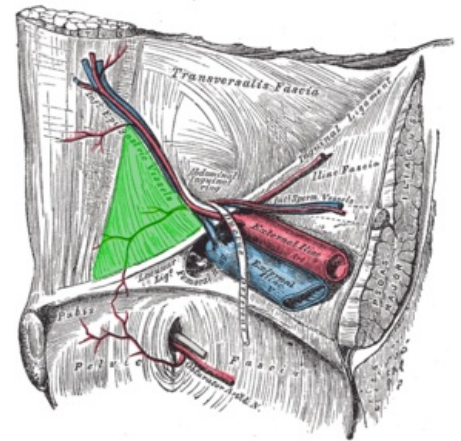
Trigonum inguinale

The trigonum inguinale (**trigonum Hesselbachi**) is a topographical site located in the regio inguinalis. It is projected in *the fossa (fovea) inguinalis medialis* . In this place, *the fascia transversalis* , which covers the muscles, is thin - it is therefore a weakened area of the abdominal wall and this is a predisposition for the formation of an inguinal hernia . **In this place, it is specifically a direct** inguinal hernia - *hernia inguinalis directa* .

Boundaries

The boundary is formed by reinforced strips of transverse fascia.

- Caudally - *ligamentum inguinale* ;
- laterally - *ligamentum interfoveolare* ;
- medially - *false inguinalis* .



inguinal trigone

Links

related articles

- Inguinal canal
- Inguinal hernias
- Inguinal canal

References

GRIM, Miloš – DRUGA, Rastislav. *Základy anatomie : Anatomie krajín těla*. - edition. Galén, 2002. 119 pp. ISBN 9788072621798.