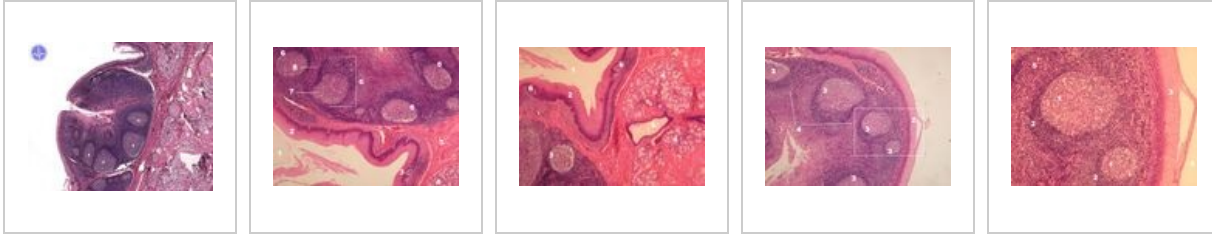
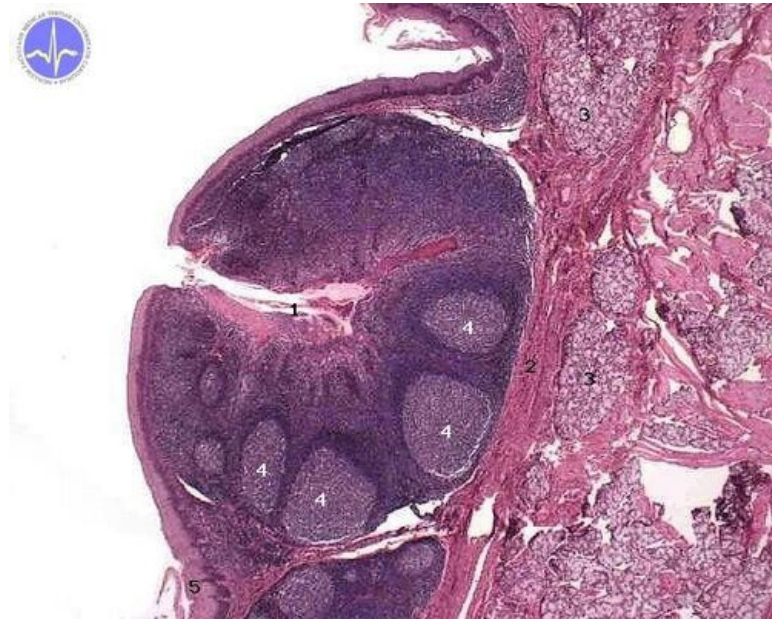


Tonsilla lingualis (SFLT)

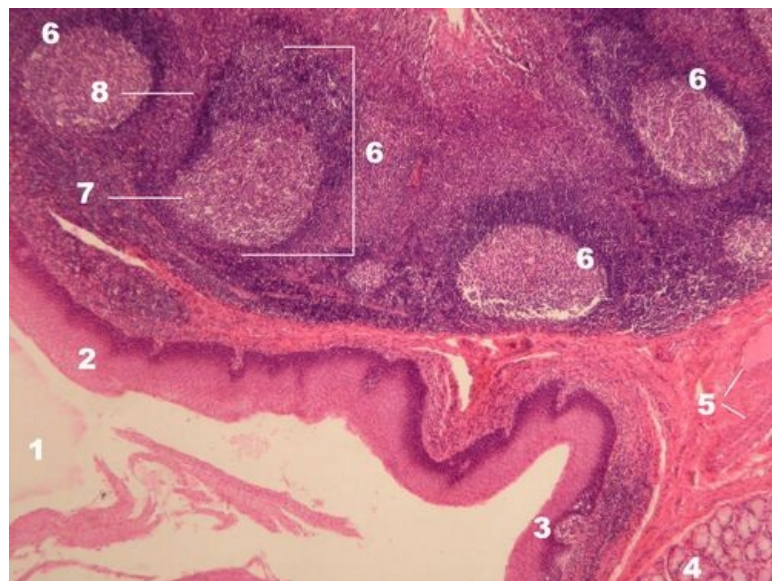


Tonsilla lingualis HE



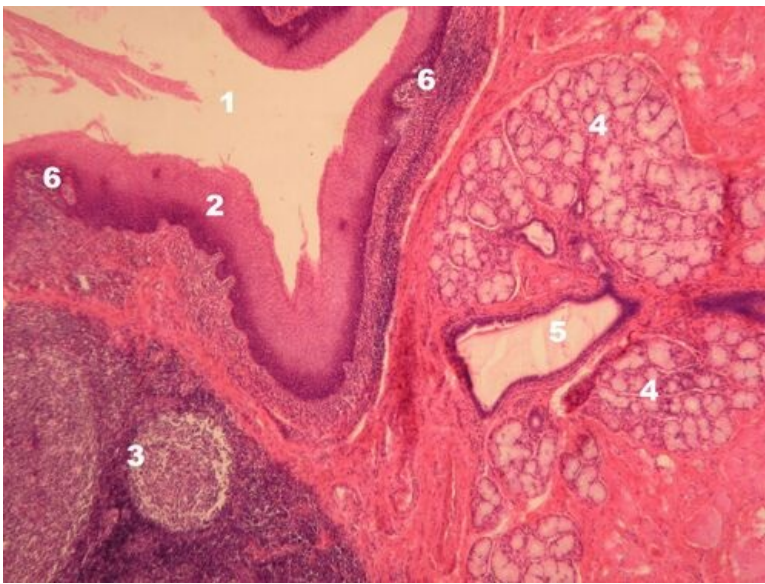
Description: 1 - crypt, 2 - fibrous capsule, 3 - mucinous glands, 4 - secondary lymphatic follicles, 5 - stratified squamous epithelium, non-keratinized.

Tonsilla lingualis HE



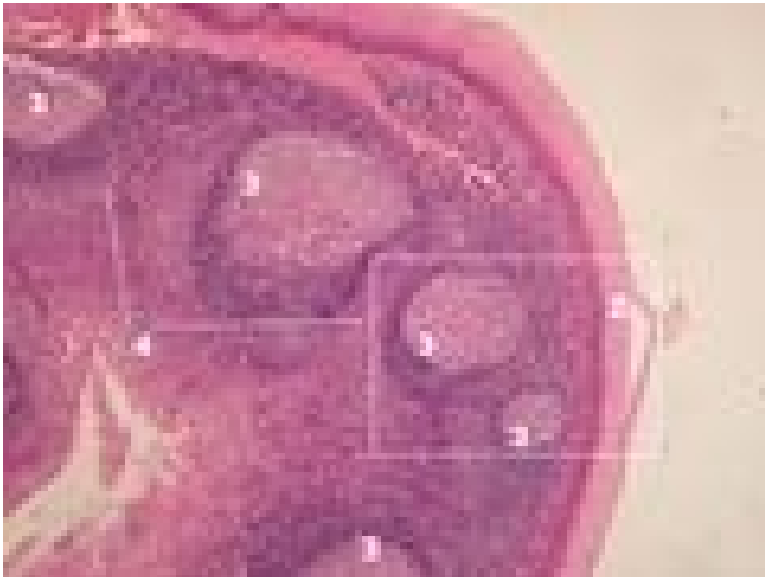
Description: 1 - lumen of the oral cavity, 2 - stratified non-keratinized squamous epithelium, 3 - follicle-associated epithelium with loosened intercellular junctions penetrating lymphocytes (FAE), 4 - mucinous glands, 5 - fibrous septum with vessels, 6 - secondary lymphatic follicle, 7 - germinal center of the follicle, 8 - lymphocytic mantle of the follicle.

Tonsilla lingualis HE



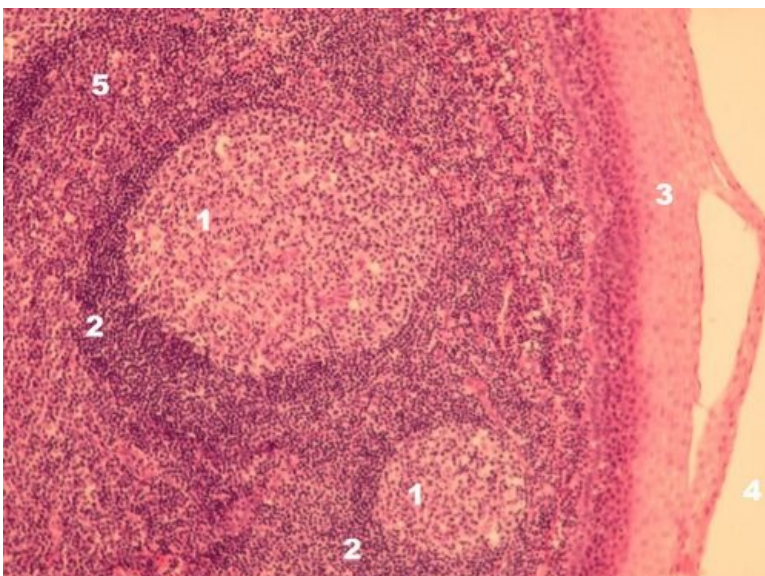
Description: 1 - crypt lumen, 2 - stratified non-keratinized squamous epithelium, 3 - lymphatic follicle, 4 - mucinous salivary glands, 5 - outlet of salivary glands, 6 - FAE.

Tonsilla lingualis HE



Description: 1 - lumen of the oral cavity, 2 - stratified non-keratinized squamous epithelium, 3 - secondary lymphatic follicles, 4 - interfollicular T-dependent zone.

Tonsilla lingualis HE - detail na lymfatické folikuly



Description: 1 - the germinal center of the secondary lymphatic follicle, 2 - the mantle zone of the sec. lymph. follicle, 3 - stratified squamous epithelium of the oral cavity, 4 - lumen of the oral cavity, 5 - interfollicular T-dependent region.

Gastrointestinal tract

- Tongue – tonsilla lingualis (SFLT)
- Gl. submandibularis (SFLT)
- Gl. parotis (SFLT)
- Gl. sublingualis (SFLT)
- Oesophagus (SFLT)
- Duodenum (SFLT)
- Small intestine(SFLT)
- Colon (SFLT)
- Appendix (SFLT)
- Liver (SFLT)
- Gallbladder (SFLT)
- Pancreas (SFLT)

Links

- Histological atlas (3. LF UK)