

# Sternum

**Sternum** (the breastbone) is a flat, unpaired bone, located at the front of the chest. It is articulated with the Clavicles and the upper seven pairs of ribs (costae verae).

## The sternum has 3 parts

- **manubrium sterni** – *the handle of the sternum*, the wider part on which there are articular surfaces for connection with the Clavicles and the first pair of ribs;
- **corpus sterni** – *corpus sterni*, it is connected to the manubrium by cartilage, contains pits for articulation with the 3rd-7th. a rib;
- **processus xiphoideus** – is a variable *sword-shaped process*.

Sex differences in the shape of the sternum lie mainly in the proportions of the body length of the sternum to the manubrium. In women, the body of the sternum is usually shorter.

## Links

### Related articles

- Ribs
- Spojení na hrudníku
- Development of the sternum

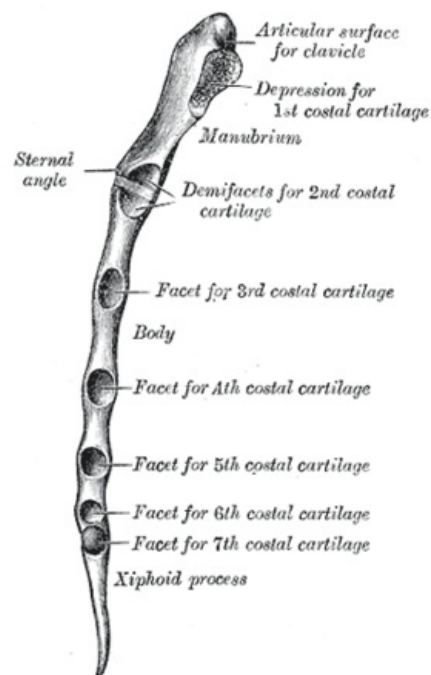
### Used literature

- ČIHÁK, Radomír. *Anatomie 1. 2.* edition. Praha : Grada, 2001. 516 pp. ISBN 978-80-7169-970-5.

Template:Navbox - bones

#### Breastbone

A02.3.03.001 (<http://www.unifr.ch/ifaa/Public/EntryPage/TA98%20Tree/Entity%20TA98%20EN/02.3.03.001%20Entity%20TA98%20EN.htm>)



Sternum – side view