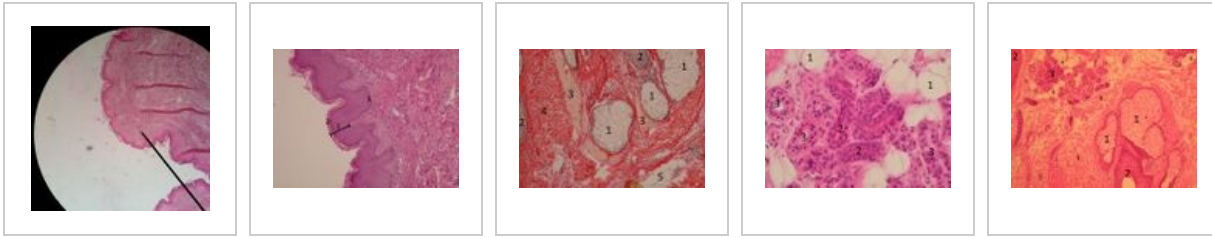


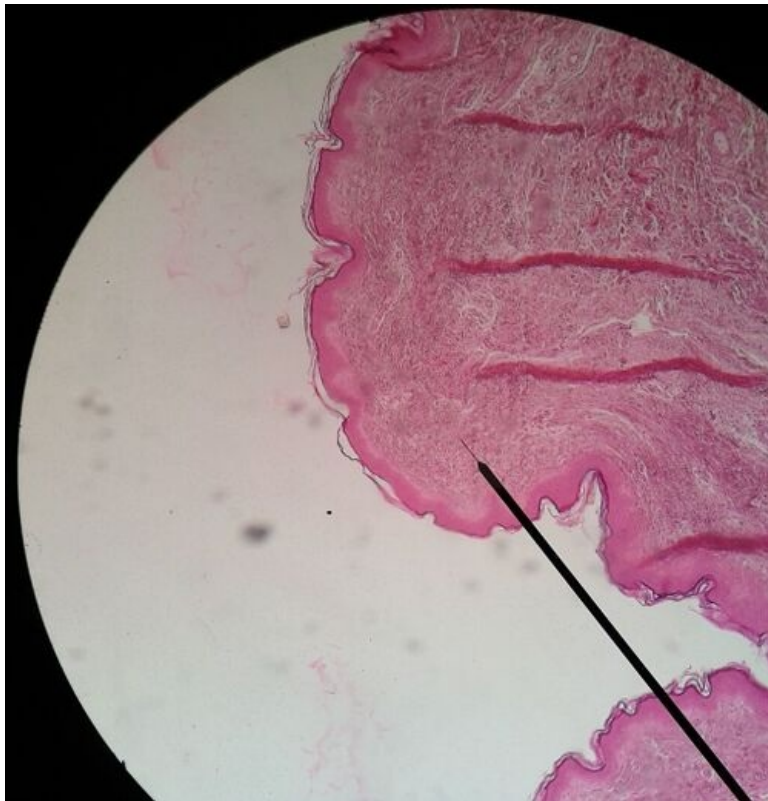Skin of the abdomen (slide)

Skin of the abdomen B8

Overview



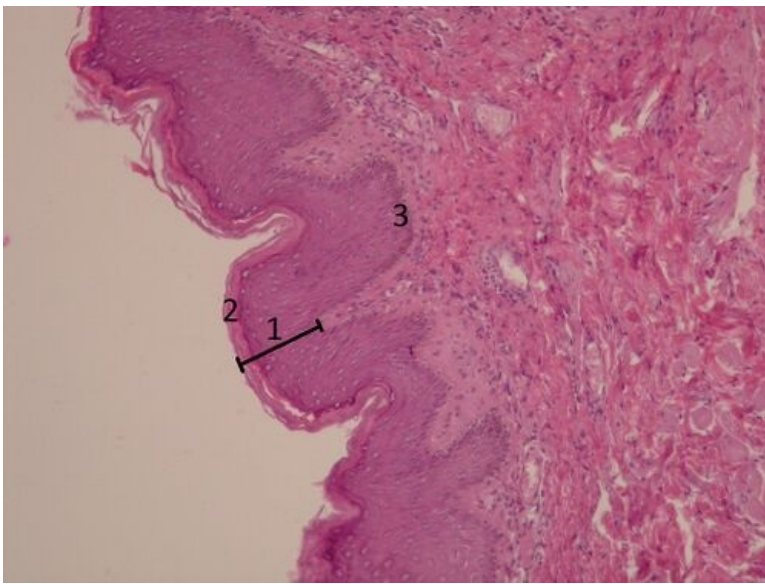
Slide 1



Name: Skin of the abdomen - clear magnification (HE)

Description: On the surface there is **keratinized stratified squamous epithelium**, under the epithelium there is **dense irregular fibrous tissue**.

Slide 2

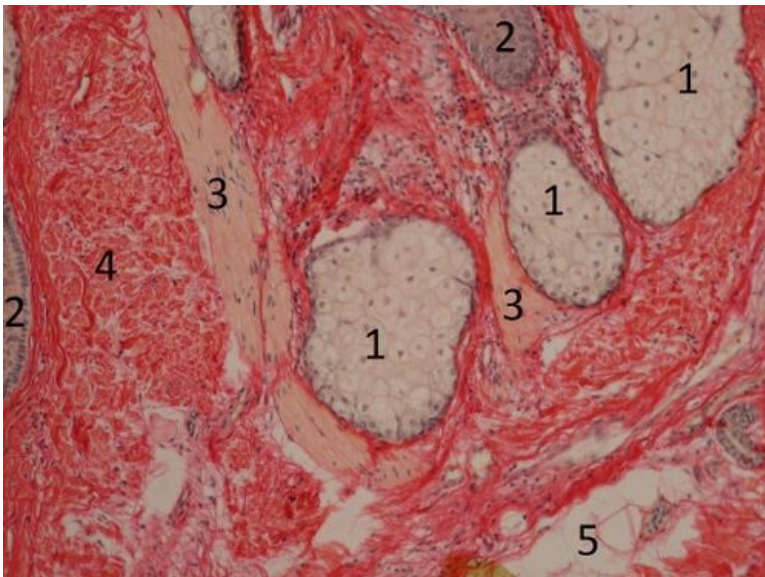


Name: Skin (HE)

Description: Epidermis - keratinized stratified squamous epithelium. Layers of the epidermis from the basal lamina: stratum basale, stratum spinosum, stratum granulosum, stratum lucidum (in thick skin, is not seen here), stratum corneum. Surface cells (str. corneum) have no nucleus. Dermis - dense irregular fibrous tissue.

1 - keratinized stratified squamous epithelium, 2 - stratum corneum 3 - stratum basale

Preparát 3

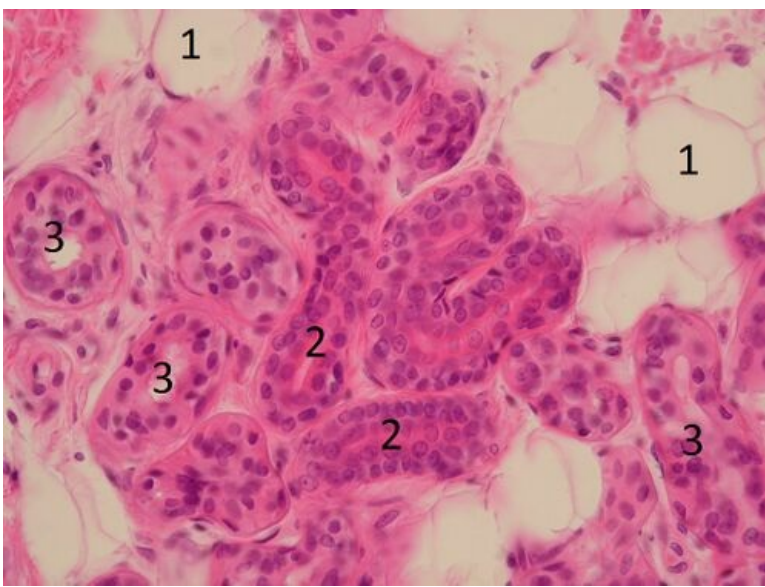


Name: Dermis of the skin (WvG)

Description: Dermis is made of dense irregular fibrous tissue. On the slide we can see a sebaceous gland (exocrine, alveolar, holocrine gland) and musculus arrector pili - a smooth muscle.

1 - sebaceous gland, 2 - hair follicle, 3 - musculus arrector pili, 4 - dense irregular fibrous tissue (main part of the dermis) 5 - fat cells

Slide 4

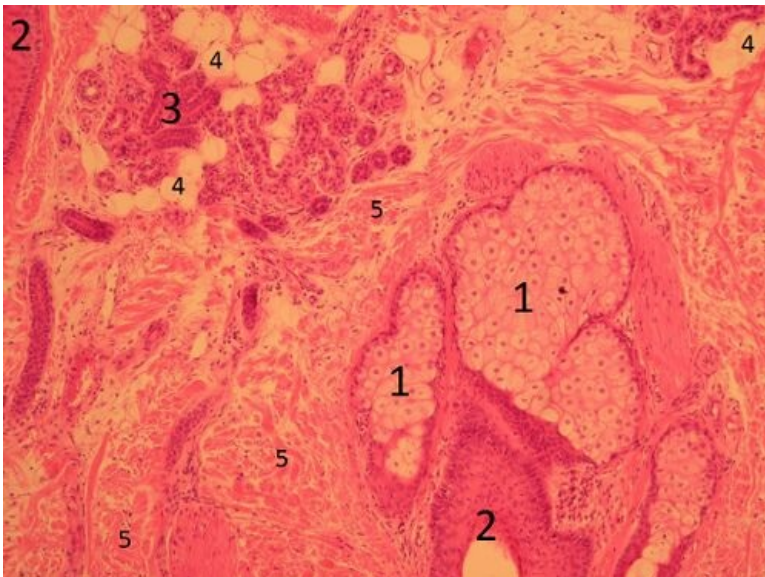


Name: Eccrine sweat glands

Description: Small sweat glands are exocrine, merocrine and eccrine (= they product granules and water), simple coiled tubular glands. The secretory unit is lighter, the duct is darker, lined by the double layered epithelium.

1 - fat cells, 2 - ducts of the sweat glands, 3 - the secretory units of the sweat glands

Slide 5



Name: Eccrine and holocrine gland

Description: On the top we can see sweat (eccrine, tubular) gland, down there is a sebaceous (alveolar, holocrine) gland, which opens into the hair follicle. The sebaceous gland is accompanied by the smooth muscle - musculus arrector pili.

1 - sebaceous gland, 2 - hair follicle, 3 - eccrine sweat gland, 4 - fat cells, 5 - dense fibrous tissue

Epithelium

- Muscular artery (slide)
- Kidney (slide)
- Thyroid gland (slide)
- Large intestine (slide)
- Fallopian tube (slide)
- Bronchus (slide)
- Bladder (slide)
- Skin of the abdomen (slide)

- Esophagus (slide)
- Vagina (slide)
- Lungs (slide)
- Small intestine (slide)
- Pancreas (slide)
- Parotis (slide)
- Submandibularis (slide)
- Mamma lactans (slide)
- Mamma nonlactans (slide)
- Stomach fundus (slide)
- Adrenal gland (slide)

Links

- Module Cell basis of the medicine (3. LF UK)

Study materials for this slide

- Skin