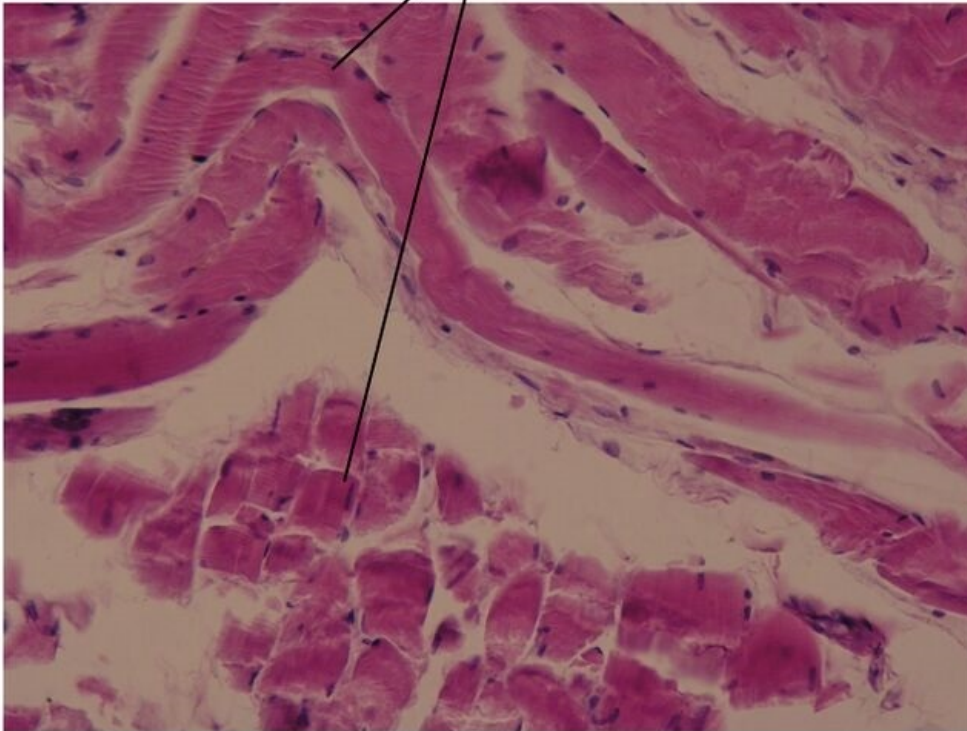


Skeletal muscle (image)

Fibres of the skeletal muscle (nuclei are situated on the periphery)



Skeletal muscle - histological slide of tongue, H&E stain

Skeletal muscle