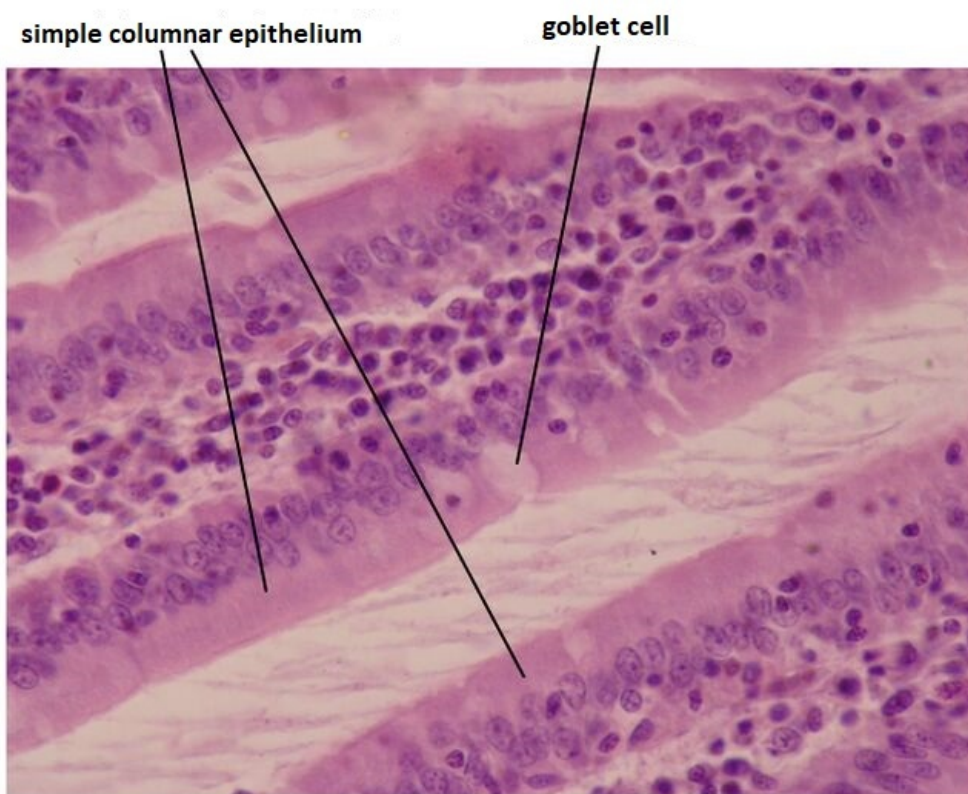


# Simple columnar epithelium (image)



**Simple columnar epithelium - duodenum slide, H&E stain**

Simple columnar epithelium