

Semitendinosus muscle

Origin: tuber ischiadicum.

Insertion: condylus medialis tibiae (pes anserinus).

Innervation: n. ischiadicus (high split: n. tibialis).

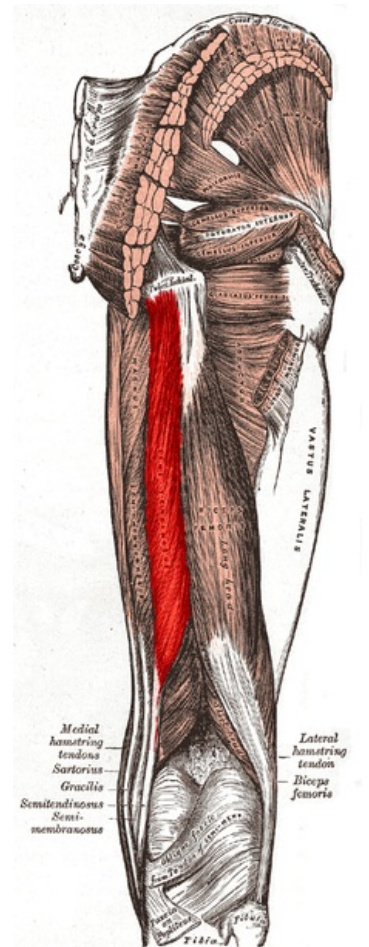
Function:

1. knee joint – flexion, internal rotation.
2. hip joint – extension;

Links

References

- ČIHÁK, . *Anatomy 1*. 2. edition. Grada, 2001. 497 pp. ISBN 80-7169-970-5.
- VIGUÉ, Jordi. *Atlas of the Human Body*. 3. edition. Rebo, 2007. ISBN 978-80-7234-881-7.



Semitendinosus muscle