

# Semimembranosus muscle

**Origin:** tuber ischiadicum.

**Insertion:** condylus medialis tibiae, m. popliteus fascia, ligamentum popliteum obliquum

The bifurcated insertion of the semimembranosus muscle is sometimes also called '*pes anserinus profundus*'.

**Innervation:** n. ischiadicus (high split: n. tibialis).

**Function:**

1. knee joint – flexion, internal rotation.
2. hip joint – extension;

## Links

### Related Articles

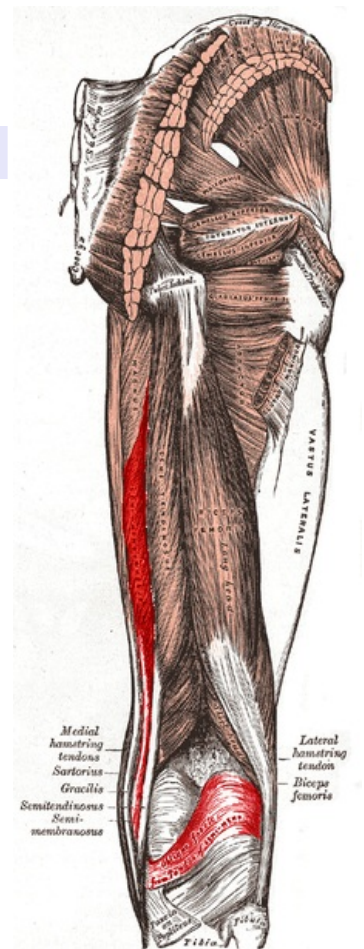
- Pes anserinus superficialis

### References

- ŠIHÁK, Radomír – GRIM, Miloš. *Anatomy*. 2nd, edit. and add edition. Grada Publishing, 2002. 470 pp. vol. 1. ISBN 80-7169-970-5.
- VIGUÉ, Jordi. *Atlas of the Human Body*. 3. edition. Rebo, 2007. ISBN 978-80-7234-881-7.

### External links

- NAŇKA, Ondřej. *Muscles and main trunks of vessels and nerves of the lower limb and main topographic formations* [online]. [cit. 2015-03-12]. <<http://anat.lf1.cuni.cz/souhrny/lekzs0502b.pdf>>.



**Semimembranosus muscle**