

Ribs

The **ribs** or *costae* are numbered in sequence. In the Latin nomenclature, the Roman numerals **costa I-XII.** are used. In the Czech designation **arabic numerals 1.-12.** are used. We describe several parts on each rib:

1. **caput costae** – head of rib,
2. **collum costae** – neck of rib,
3. **corpus costae** – rib body,
4. **tuberculum costae** – rib tubercle.

On the bony main part of the rib – **os costae** there are:

1. **sulcus costae** – a shallow groove on the lower side,
2. **crista costae** – lower edge of the rib,
3. **angulus costae** – rib curvature.

Articular faces on the rib

- **Facies articularis capitis costae** – is the articular surface on the head of the rib, for **II.-IX.** the rib is divided by *crista capitis costae* into two surfaces, because these ribs are connected to two adjacent vertebrae.
- **Facies articularis tuberculi costae** – this surface on the tubercle of the rib connects to the transverse process of the vertebrae.
- **Free ends of costal cartilages** – surfaces that connect the rib to the sternum or to the previous rib.

Types of ribs

- **Costae verae** – are the true ribs, **the first 7 pairs.** These ribs are directly articulated anteriorly to the sternum by means of their cartilage.
- **Costae spuriae** – are the false ribs, **8.-10..** These ribs are articulated by their cartilages with the cartilages of the previous ribs.
- **Costae fluctuantes** – are the free ribs. It is the **11.** and **12.** pair. These ribs terminate freely in the muscles of the abdominal wall.

Shape differences of the ribs

Some ribs differ from the general shape.

- **Costa I.** – on the first rib there is an imprint of the subclavian artery – *sulcus arteriae subclaviae* and roughness for muscle attachment – *tuberculum musculi scaleni anterioris* and roughness for *musculus scalenus medius*.
- **Costa II.** – roughness for *scalenus posterior muscle* and *tuberositas musculi serrati anterioris*.
- **Costa XI. et XII.** – they are slightly curved and lack a *tuberculum*.

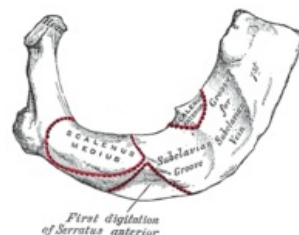
Links

Related articles

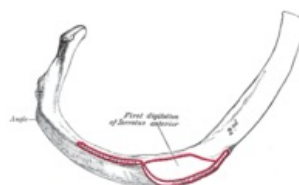
- Bone

Recommended Literature

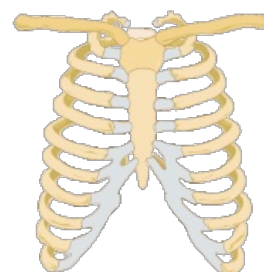
- ČIHÁK, Radomír. *Anatomie 1.* 2. edition. Grada Publishing, a.s., 2008. vol. 1. pp. 516. ISBN 80-7169-970-5.



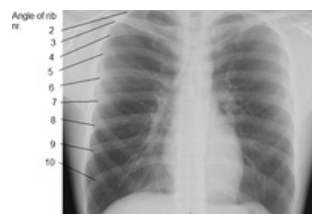Rib I.



Rib II.



Rib cage.



chest X-ray; ribs highlighted.