

Rib cage

Rib cage, *thorax* in latin.

Sternum

the rib cage protects the organs encased within

Sternum (the breastbone) is a flat, unpaired bone, located at the front of the chest. It is articulated with the Clavicles and the upper seven pairs of ribs (costae verae).

The sternum has 3 parts

- **manubrium sterni** – *the handle of the sternum*, the wider part on which there are articular surfaces for connection with the Clavicles and the first pair of ribs;
- **corpus sterni** – *corpus sterni*, it is connected to the manubrium by cartilage, contains pits for articulation with the 3rd-7th. a rib;
- **processus xiphoideus** – is a variable *sword-shaped process*.

Sex differences in the shape of the sternum lie mainly in the proportions of the body length of the sternum to the manubrium. In women, the body of the sternum is usually shorter.

Ribs

The ribs or *costae* are numbered in sequence. In the Latin nomenclature, the Roman numerals **costa I-XII.** are used. In the Czech designation **arabic numerals 1.-12.** are used. We describe several parts on each rib:

1. **caput costae** – head of rib,
2. **collum costae** – neck of rib,
3. **corpus costae** – rib body,
4. **tuberculum costae** – rib tubercle.

On the bony main part of the rib – **os costae** there are:

1. **sulcus costae** – a shallow groove on the lower side,
2. **crista costae** – lower edge of the rib,
3. **angulus costae** – rib curvature.

Articular faces on the rib

- **Facies articularis capitis costae** – is the articular surface on the head of the rib, for **II.-IX.** the rib is divided by *crista capitis costae* into two surfaces, because these ribs are connected to two adjacent vertebrae.
- **Facies articularis tuberculi costae** – this surface on the tubercle of the rib connects to the transverse process of the vertebrae.
- **Free ends of costal cartilages** – surfaces that connect the rib to the sternum or to the previous rib.

Types of ribs

- **Costae verae** – are the true ribs, **the first 7 pairs.** These ribs are directly articulated anteriorly to the sternum by means of their cartilage.
- **Costae spuriae** – are the false ribs, **8.-10.** These ribs are articulated by their cartilages with the cartilages of the previous ribs.
- **Costae fluctuantes** – are the free ribs. It is the **11.** and **12.** pair. These ribs terminate freely in the muscles of the abdominal wall.

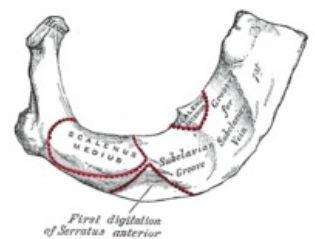
Shape differences of the ribs

Some ribs differ from the general shape.

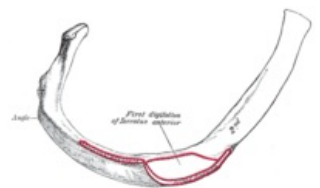
- **Costa I.** – on the first rib there is an imprint of the subclavian artery – *sulcus arteriae subclaviae* and roughness for muscle attachment – *tuberculum musculi scaleni anterioris* and roughness for *musculus scalenus medius*.
- **Costa II.** – roughness for *scalenus posterior muscle* and *tuberositas musculi serrati anterioris*.

Breastbone

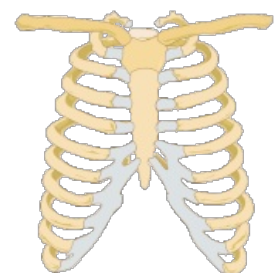
A02.3.03.001 (<http://www.unifr.ch/ifaa/Public/EntryPage/TA98%20Tree/Entity%20TA98%20EN/02.3.03.001%20Entity%20TA98%20EN.htm>)



Rib I.



Rib II.



Rib cage.

- **Costa XI. et XII.** – they are slightly curved and lack a *tuberculum*.

Links

Related articles

- Bone

Recommended Literature

- ČIHÁK, Radomír. *Anatomie 1*. 2. edition. Grada Publishing, a.s., 2008. vol. 1. pp. 516. ISBN 80-7169-970-5.

Connections on the chest

Connections on the chest

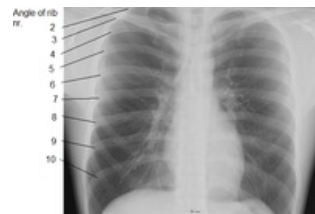Links

Related articles

- Chest muscles
- Spine
- General anatomy of joints

Used literature

- ČIHÁK, Radomír. *Anatomie 1*. 2. edition. Praha : Grada Publishing, a.s., 2008. 516 pp. vol. 1. ISBN 80-7169-970-5.



chest X-ray; ribs highlighted.