

Retromalleolar regions (medial + lateral)

Medial Malleolus

Canalis Malleolaris (Behind malleolus)

Passage behind medial malleolus is also known as *canalis malleolaris* (tarsal canal). It is margined by **medial malleolus (ventral)**, **flexor retinaculum (medial)** and **tuber of the calcaneus (dorsal)**.

The mnemonic **TI DI VA NE H** or "**Tom, Dick and Very Nervous Harry**" shows the content and position of the canal in Ventrodorsal order:

Tendon of *m. tibialis posterior* in its tendinous sheath;

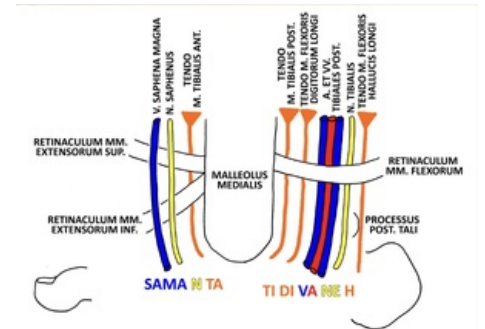
Tendon of *m. flexor digitorum longus* also in its sheath;

Posterior tibial veins (2) and artery (1), in Vein, Artery, Vein format

Tibial nerve

Tendon of *m. flexor hallucis longus* in its sheath

All the structures are covered by *flexor retinaculum* and lean on medial malleolus. Exception is tendon of *m. flexor hallucis longus*, which is from all structures the most dorsal and runs in groove in posterior process of talus (groove for tendon of flexor hallucis longus on the talus).



"SAMA N TA" & "TI DI VA NE H" (schematic)

Structures in front of medial malleolus

Passage in front of the medial malleolus is margined by superior and inferior *extensor retinaculum* (ventral).

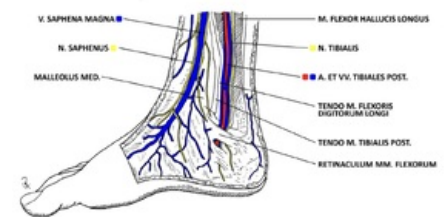
The content is easier remembered by **SAMA N TA**:

Vena saphena magna (great saphenous vein)

Saphenous nerve

Tendon of *m. tibialis anterior* in its tendinous sheath.

Veins and nerve run superficially - over superior and inferior extensor retinaculum. Tendons run deeper to the retinaculum.



Structures around the medial malleolus

Lateral Malleolus

Passage behind the **lateral malleolus (ventral)** is margined by superior and inferior fibular **retinaculum (lateral)** and **tuber calcanei (dorsal)**.

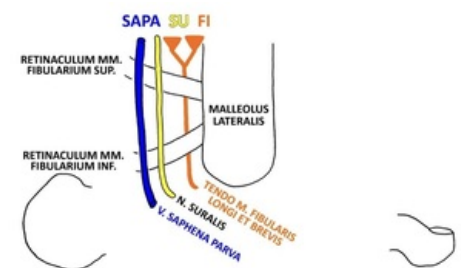
Structures which run in this topographical region can be remembered by mnemonic **SAPA SU FI**:

Vena saphena parva (small saphenous vein)

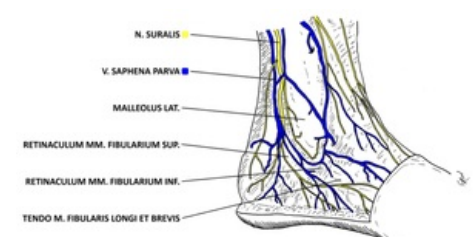
Sural nerve

Tendon of *m. fibularis longus et brevis*

Similar as in structures in front of medial malleolus, veins with the nerve run superficially (over retinaculum), and insertion tendon of muscles run deeper to the retinaculum



"SAPA SU FI" (schematic)



Structures behind the lateral malleolus