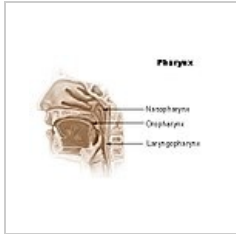


Pharynx - description, divisions, muscles, syntopy, vascular supply, innervation

The pharynx is the transitional space between the oral cavity and the respiratory and digestive systems. The pharynx is lined by stratified, non-keratinised squamous epithelium. It is divided into three sections: nasopharynx, oropharynx and laryngopharynx.



The Pharynx

Nasopharynx

- Base to C2
- Respiratory function
- Superior to the soft palate; posterior expansion of the nasal cavity

Oropharynx

- C2 to C4
- Digestive function
- Superior to the soft palate; inferior to the tongue
- Lateral to it are the palatoglossal and palatopharyngeal arches

Laryngopharynx

- C4 to C6
- Superior border is epiglottis
- Inferior border is cricoid cartilage

Blood Supply

Arteries

- Ascending pharyngeal artery , external carotid artery medial group
- Ascending palatine artery , from facial artery of external carotid artery
- Tonsillar artery ,
- Maxillary artery
- Lingual artery

Veins

- Pterygoid venous plexus
- Facial vein
- Internal Jugular Vein

Innervation

- Motor and most sensory innervation is done by glossopharyngeal nerve

Muscular Innervation

- Stylopharyngeus - glossopharyngeal nerve
- All other muscles of the pharynx - pharyngeal plexus

Sensory

- Nasopharynx - pharyngeal branch of the maxillary nerve
- Oropharynx - glossopharyngeal nerve

- Laryngopharynx - vagus nerve

Swallowing Reflex

- It is the voluntary initiation of swallowing
1. Reflex closure of the airway
 2. Reflex transport of food bolus down the oesophagus; through the pharynx

Links

Bibliography

SNELL, Richard S. *Clinical Anatomy by Regions*. 8th Edition edition. 2004. ISBN 978-0-7817-6404-9.