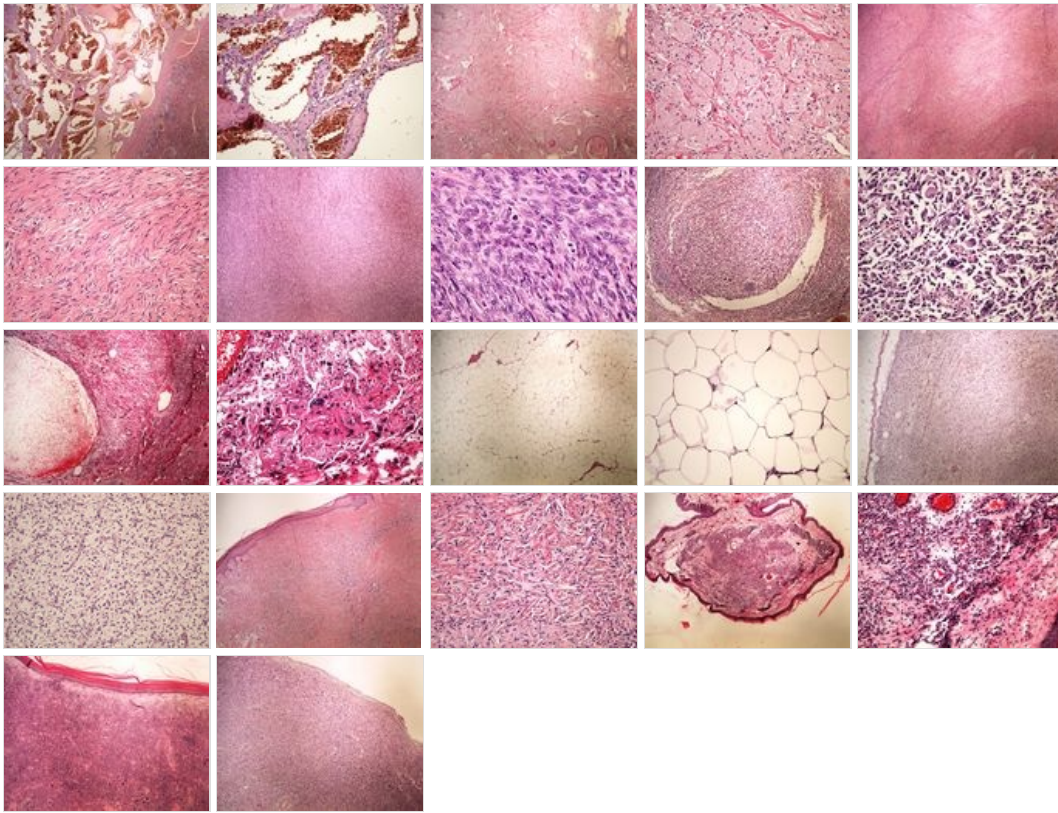
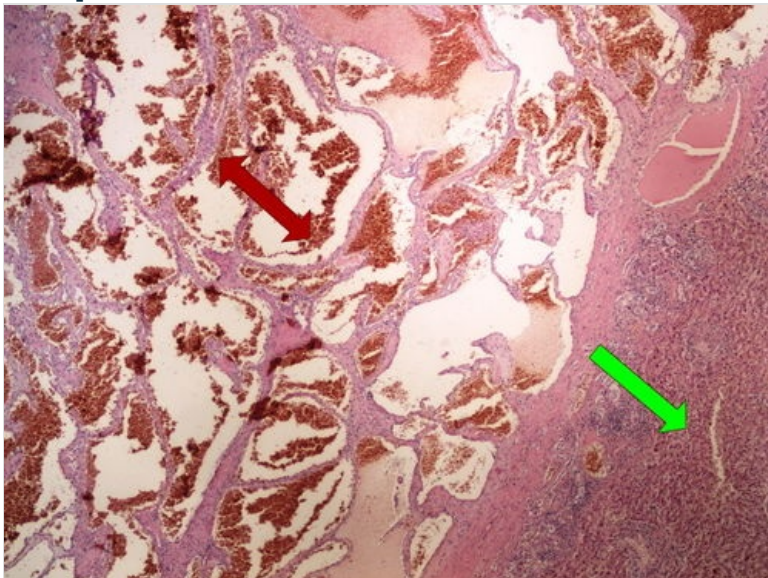


# OZPP module - Practicum No. 10

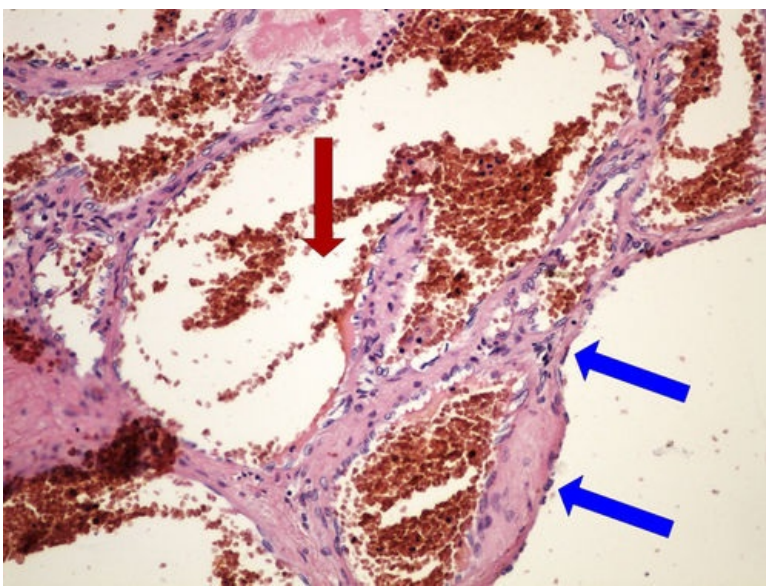
## Overview



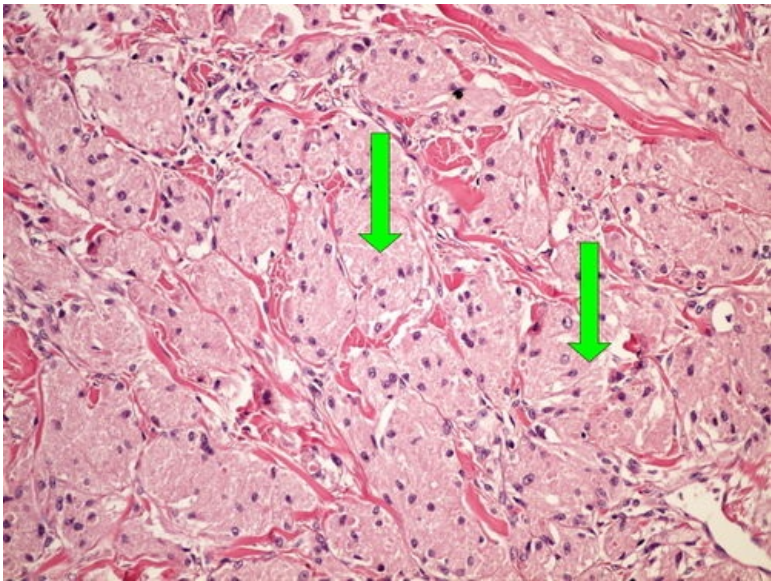
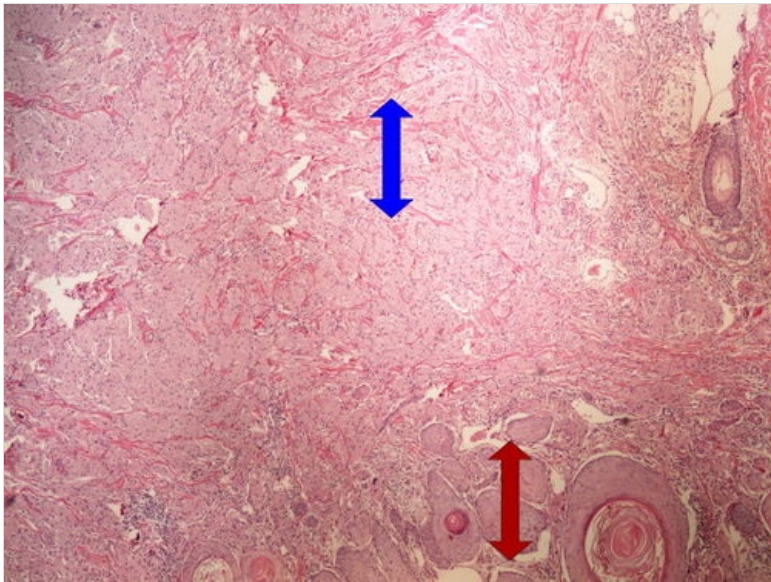
## Preparation No. 1 and No. 2 - cavernous hemangioma of the liver







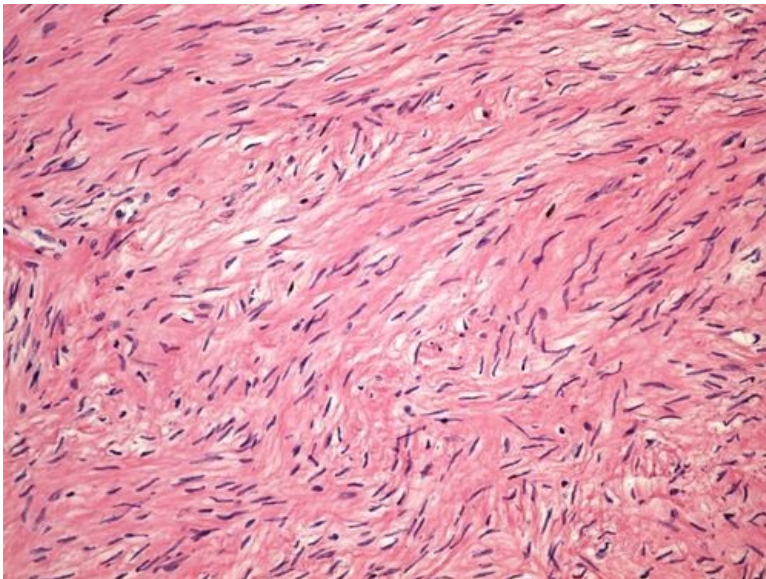
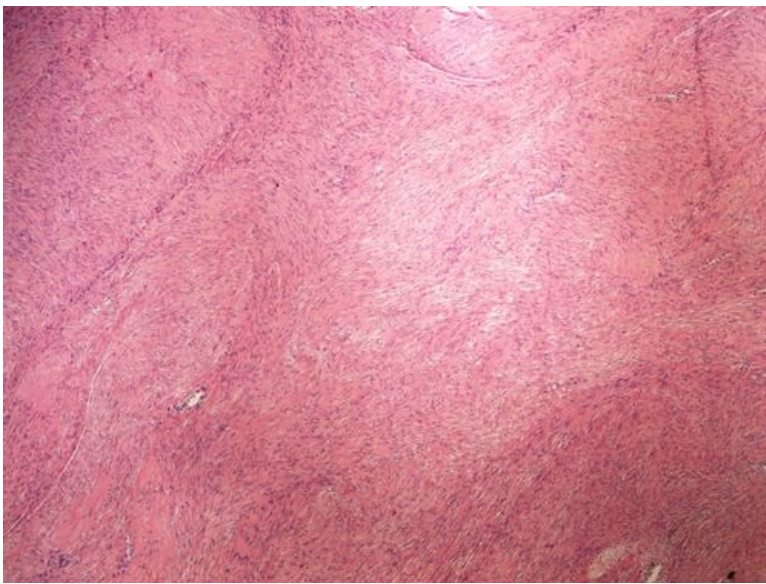
**Preparation No. 3 and No. 4 -** [Expand]  
**tumor from granular cells**



**Structures** [Expand]

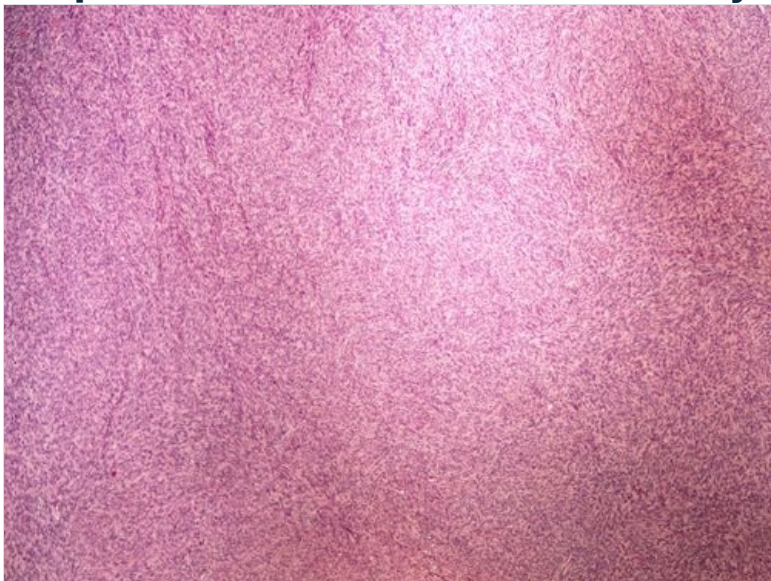**Preparation No. 5 and No. 6 - uterine leiomyoma**



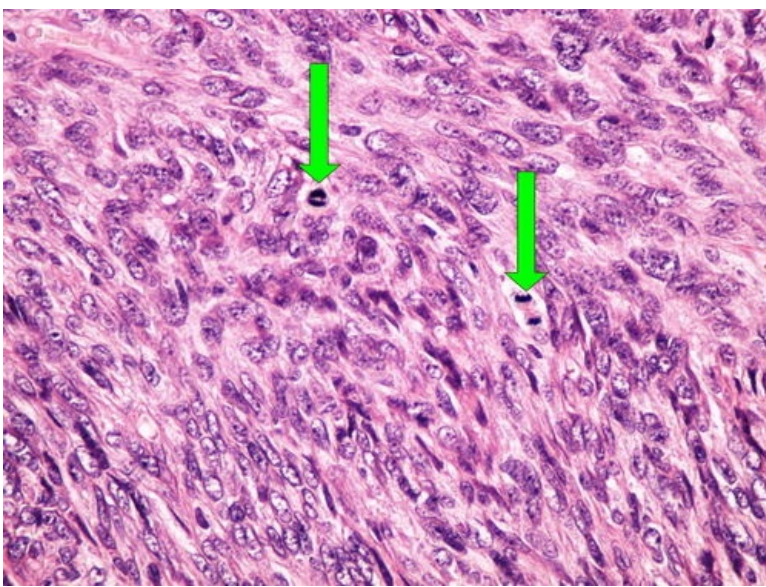


**Structures** [\[Expand\]](#)

**Preparation no. 7 and no. 8 - leiomyocellular sarcoma**





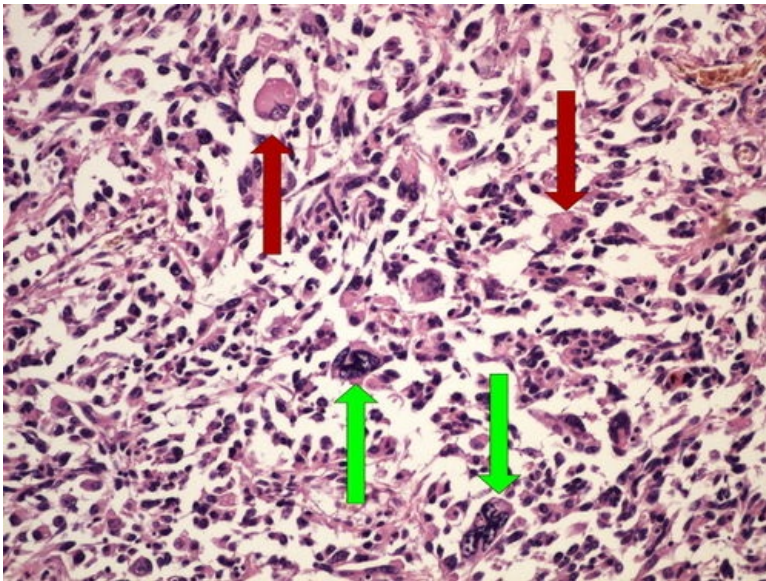
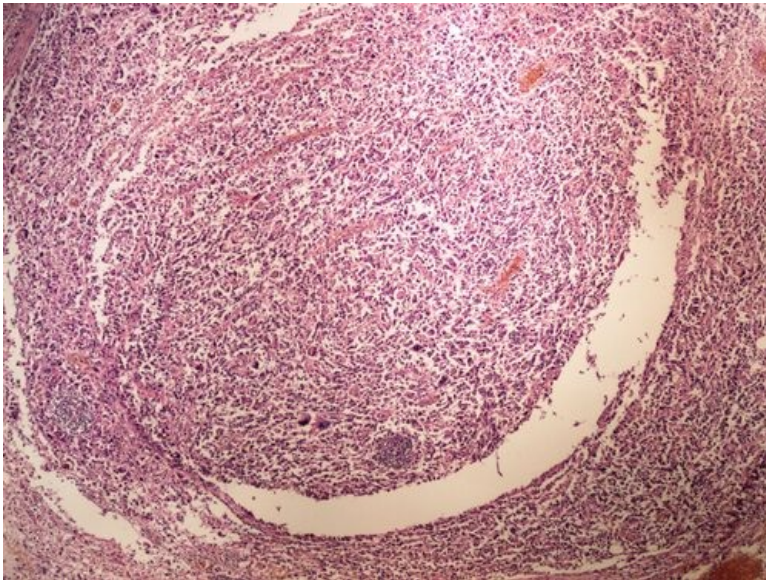


**Structures**

[Expand]

- higher cellularity than in preparation No. 5

**Preparation no. 9 and no. 10 - polymorphocellular sarcoma**

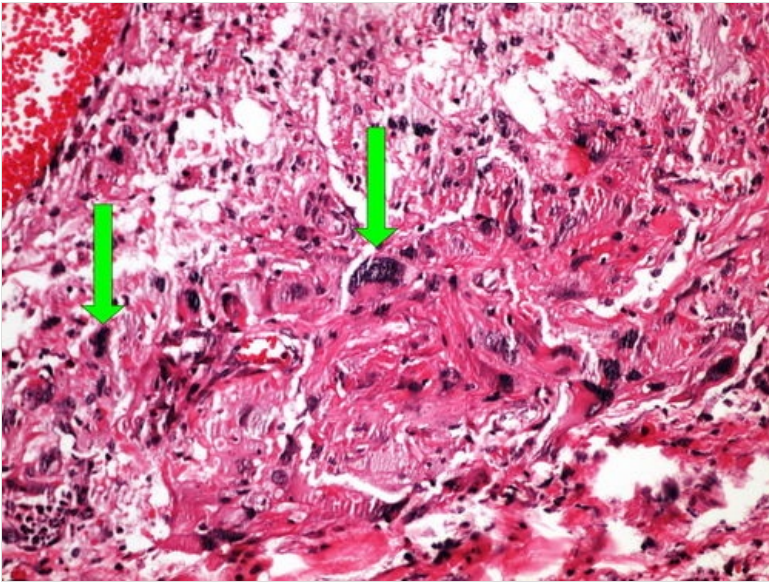
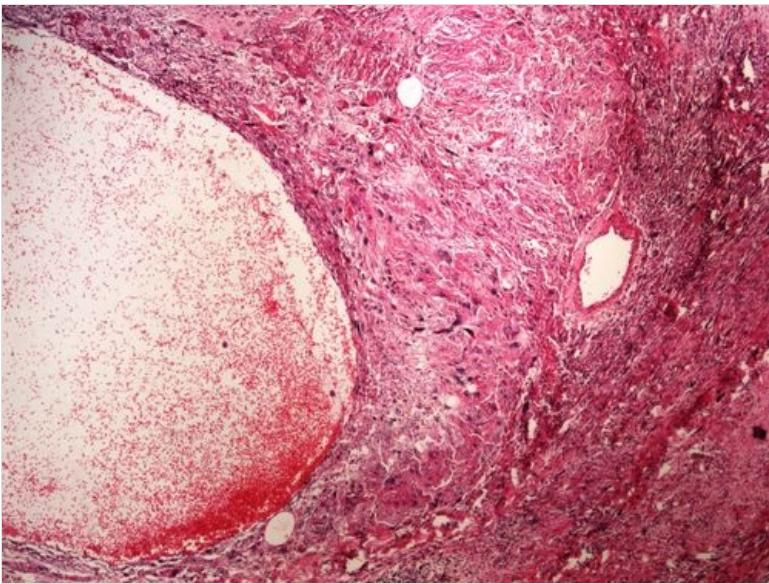


**Structures**

[Expand]

**Preparation No. 11 and No. 12 - rhabdomyosarcoma**

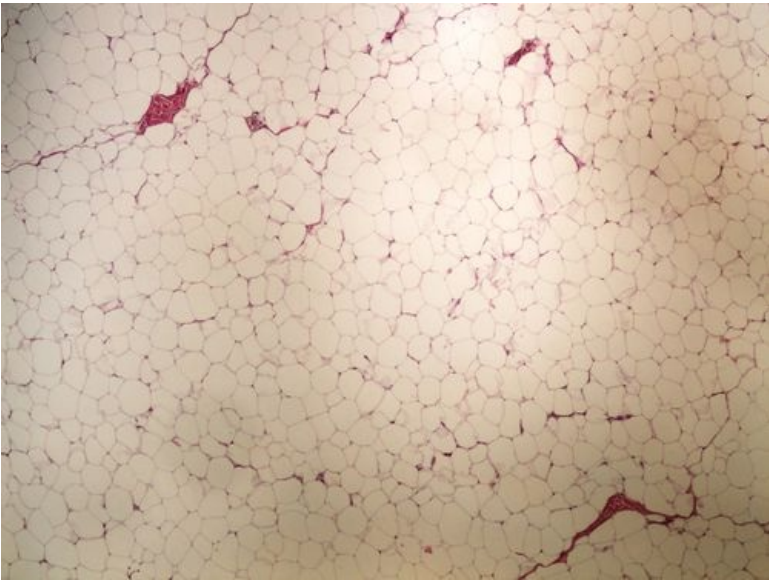




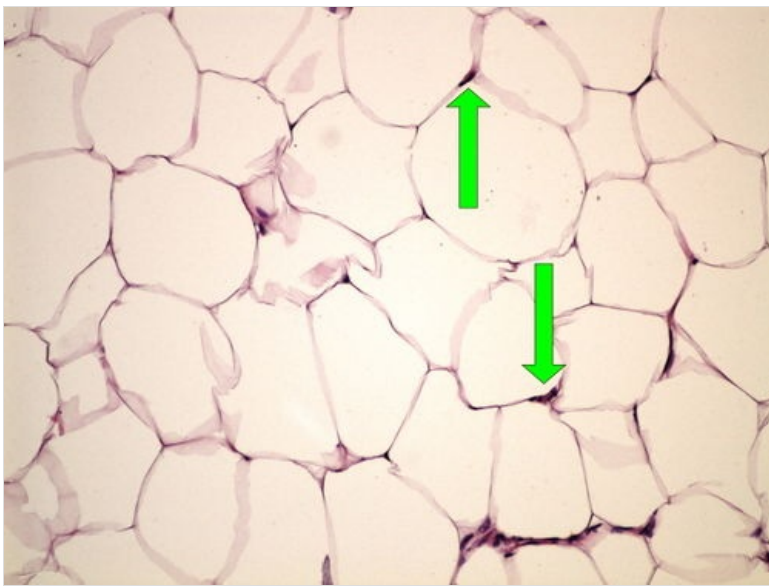
**Structures**

[Expand]

**Preparation No. 13 and No. 14 - lipoma**



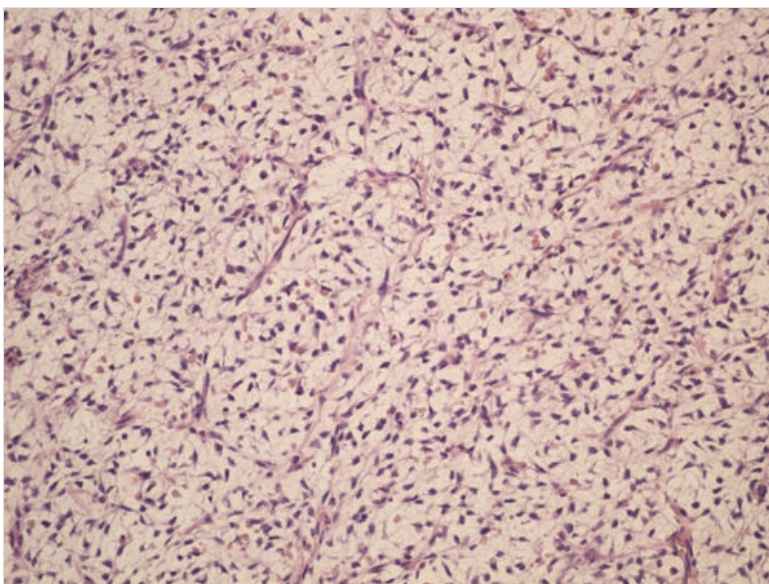
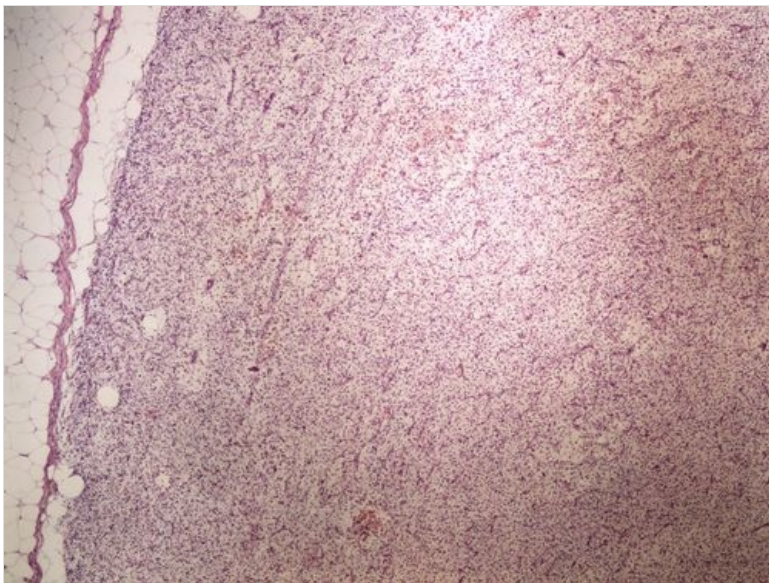




**Structures**

[Expand]

## **Preparation No. 15 and No. 16 - liposarcoma**

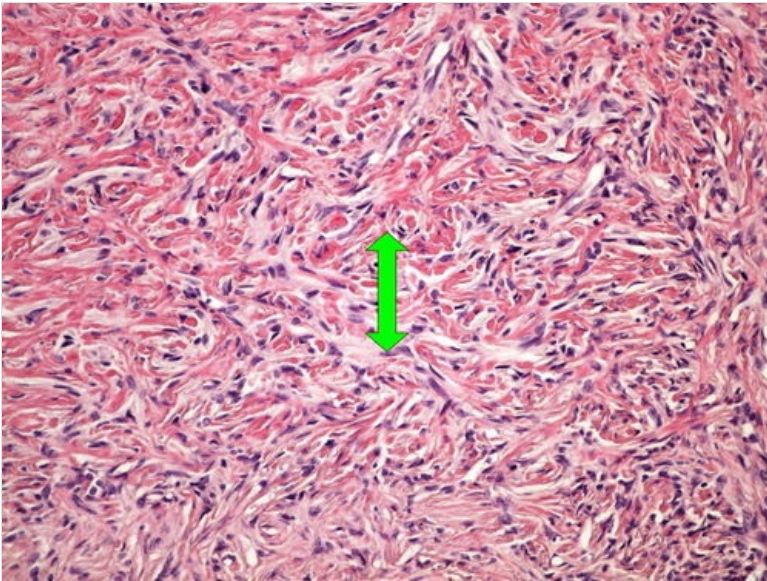
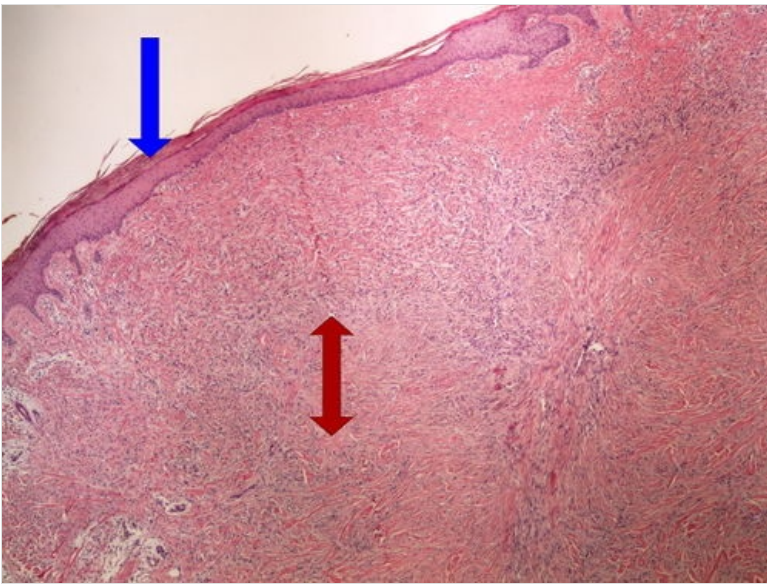


**Struktury**

[Expand]

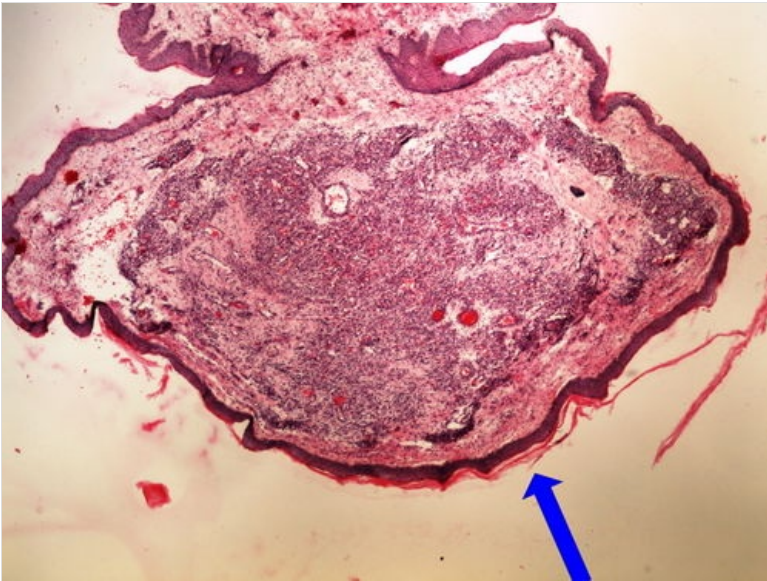
## **Preparation No. 17 and No. 18 - dermatofibroma**



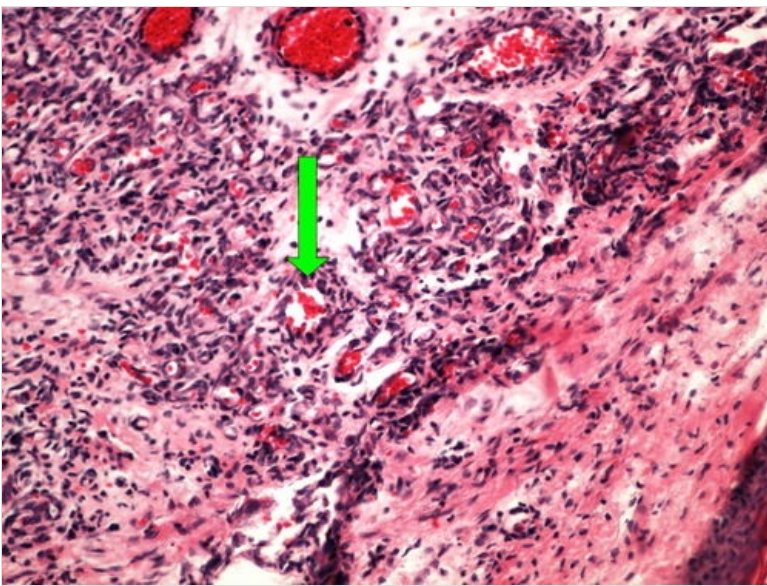


**Struktury** [\[Expand\]](#)

**Preparation No. 19 and No. 20 - capillary hemangioma of the skin**

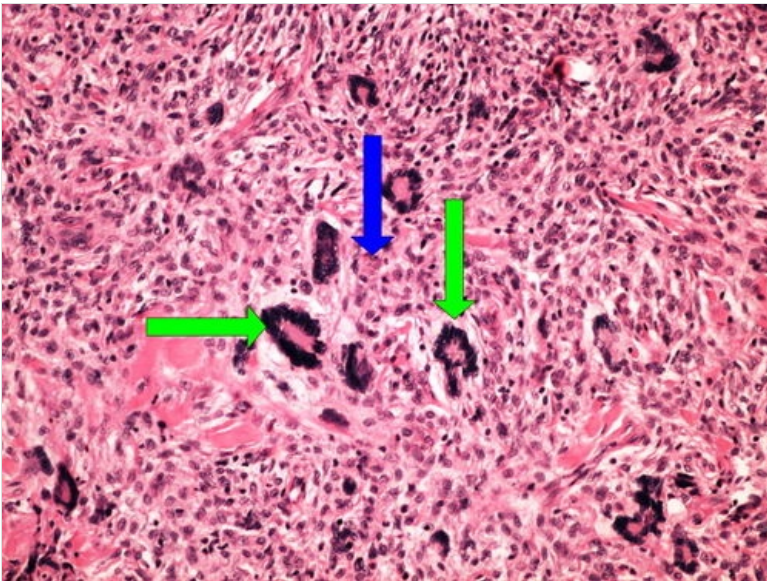
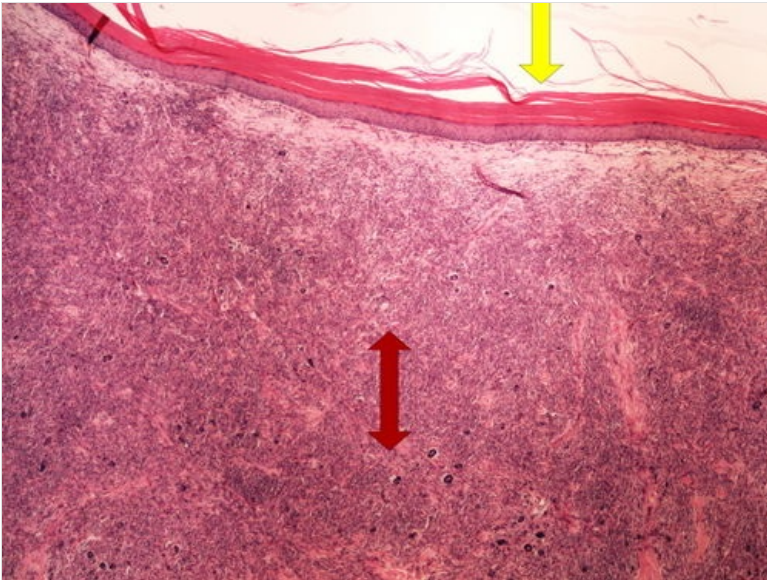






Structures [Expand]

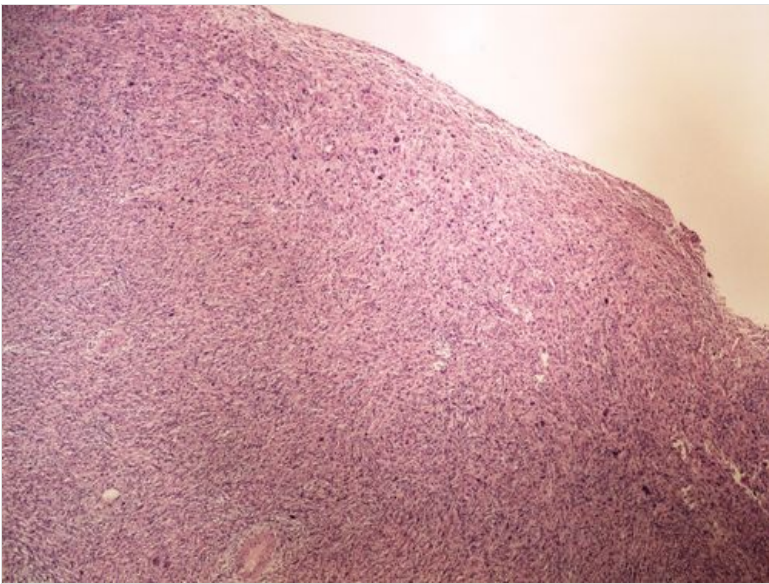
**Preparation no. 21 and no. 22 - fibroxanthoma**



Structures [Expand]

**Preparation no. 23 - malignant fibrous histiocytoma**





**Navigation**

Modul OZPP - Practice Number  
9

Module General Basics of  
Pathology and Pathophysiology  
(3rd Faculty of Medicine,  
Charles University)

← Modul OZPP - Practice  
Number 11→