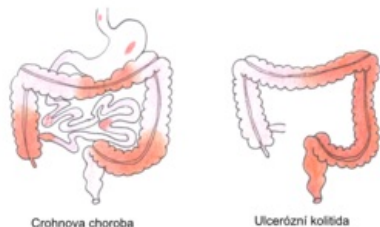


# Nonspecific Intestinal Inflammations

**Nonspecific intestinal inflammations** <sup>[1]</sup> include Crohn's disease (*ileitis terminalis*) a ulcerative colitis (*proctocolitis idiopathica*). These are chronic inflammatory diseases of the digestive tract, which are often accompanied by abundant extraintestinal symptoms. Both diseases begin in childhood or adolescence and their etiology is unclear. The incidence and prevalence of nonspecific intestinal inflammation has been increasing in recent years, 20-30 % of the patients are children under 18 years of age.<sup>[2]</sup>



## Crohnova choroba

It is a chronic non-specific inflammation of the small or large intestine (or any part of the GIT). It is a segmental or multisegmental, transmural, typically granulomatous inflammation.

## Ulcerative colitis

Non-specific hemorrhagic-catarrhal or ulcerative inflammation of the rectum and the adjacent part (or the entire colon) with a sudden or chronically exacerbating course.

## Indeterminate colitis

It is an inflammation of the large intestine with characteristic overlapping features of Crohn's disease and ulcerative colitis or with various atypical signs, thanks to which the disease cannot be conclusively classified. <sup>[2]</sup>

	<b>Crohnova choroba</b>	<b>ulcerózní kolitida</b> <sup>[3][2]</sup>
localization	the entire digestive tract, most often the terminal ileum	rectum a colon
type of damage	segmental (alternation of inflammatory and unaffected sections)	continuous progression in the oral direction
Abdominal X-ray	intestinal wall thickening, stenosis	the disappearance of haustration
endoscopy	discontinuous damage, focal aphthae, linear ulcers	hemorrhagic mucosa, diffuse inflammation, pseudopolyps
histology	inflammation of all layers of the intestinal wall (transmural)	inflammation of the mucous membranes and submucosa
	typical epithelioid granulomas, lymphocytic infiltrates	cryptitis, cryptic abscesses
klinický obraz	abdominal pain, diarrhea - rarely with blood	bloody diarrhea with tenesms
	fever, weight loss, anorexia, growth retardation	
complication	formation of fistulas, stenoses and abscesses	increased risk of carcinoma

 For more information see *Crohn's disease*.

 For more information see *Ulcerative colitis*.

## Links

## Related articles

- Autoimmune diseases • Diarrheal diseases (signpost) • Pseudomembranous enterocolitis

## External links

- ZÁDOROVÁ, Zdena. *Czech Gastroenterological Society : Nonspecific intestinal inflammations* [online]. ©2007. The last revision 2009-01-23, [cit. 2010-05-02]. <<https://www.cgs-cls.cz/informace-pro-pacienty/nespecificke-strevni-zanety/>>.

## References

1. ŠERCLOVÁ, Z, et al. *Recommended procedures for surgical treatment of patients with non-specific intestinal inflammation - Part 1: preoperative preparation* [online]. ©2015. [cit. 2019-06-07]. <<https://www.cgs-cls.cz/wp-content/uploads/2017/02/06.pdf>>.
2. LEBL, J – JANDA, J – POHUNEK, P, et al. *Klinická pediatrie*. 1. edition. Galén, 2012. 698 pp. pp. 311-318. ISBN 978-80-7262-772-1.
3. MUNTAU, Ania Carolina. *Pediatrie*. 4. edition. Prague : Grada, 2009. pp. 372-377. ISBN 978-80-247-2525-3.

Kategorie:Gastroenterologie Kategorie:Patofyziologie Kategorie:Patologie Kategorie:Pediatrie Kategorie:Vnitřní lékařství Kategorie:Imunologie