

Nasal cavity (boundaries, sinus openings), vessels and nerves

Boundaries of Nasal Cavity

Superior Boundaries

1. Nasal bones
2. Nasal part of frontal bone
3. Cribriform plate (ethmoid bone)
4. Sphenoid bone

Lateral Boundaries

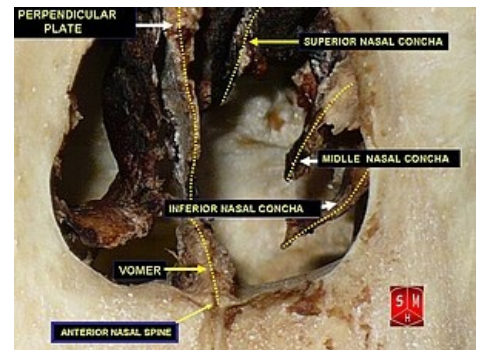
1. Nasal Bone
2. Lacrimal Bone
3. Ethmoid Bone
4. Inferior Nasal Concha (or turbine)
5. Palatine Bone
6. Medial Pterygoid of Sphenoid Bone
7. Maxilla Bone

Medial Boundaries

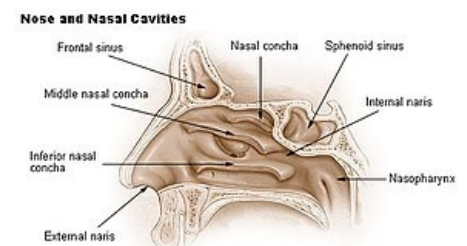
1. Nasal septum mucous part
2. Cartilaginous part - Septal cartilage
3. Bony part - Perpendicular plate of ethmoid bone & Vomer

Inferior Boundaries

1. Horizontal plate of palatine bone
2. Palatine process of maxilla



Anterior and external view of nasal cavity



Nose and nasal cavities

Sinus Openings

Sphenoethmoidal Recess Sinus Openings

1. Sphenoid sinus

Superior Nasal Meatus Sinus Openings

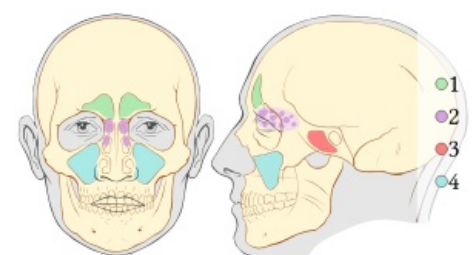
1. Posterior ethmoidal air cells

Middle Nasal Meatus Sinus Openings

1. Frontal sinus (semilunar hiatus)
2. Anterior ethmoidal air cells (semilunar hiatus)
3. Maxillary sinus (semilunar hiatus)
4. Middle ethmoidal air cells (*bullae ethmoidalis*)

Inferior Nasal Meatus Sinus Openings

1. Nasolacrimal duct



Paranasal sinuses

Vessels of Nasal Cavity

Arterial Supply

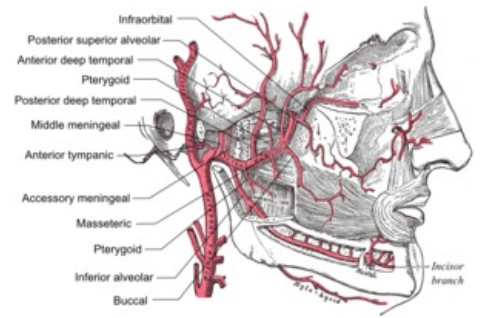
The nasal cavity receives innervation from both external and internal carotid arteries.

Branches from external carotid artery include:

- Maxillary -> Sphenopalatine
- Maxillary -> Descending palatine -> Greater palatine
- Facial -> Superior labial

Branches from Internal carotid artery include:

- Ophthalmic -> Anterior & posterior ethmoidal



Maxillary artery branches

Arterial Supply of Lateral Nasal Wall

- Posterior lateral nasal branch (sphenopalatine)
- Anterior ethmoidal branches
- Middle ethmoidal branches
- Lateral nasal branches of superior labial artery

Arterial Supply of Medial Nasal Wall

- Nasopalatine artery
- Greater palatine artery

Links

Related Articles

Bibliography

References