

# Mycosis fungoides

**Mycosis fungoides** is an epidermoid cutaneous T-lymphoma characterized by the proliferation of small or medium-sized lymphocytes. It primarily affects the skin, but may gradually develop to form squamous foci with gradual tumor formation, lymph node and internal organ involvement.

## Clinical picture

Development takes years (without treatment 10-15 years). Gradual development in stages.

1. **Premycotic stage:** in the form of so-called *parapsoriasis en plaques* (formation of peeling areas on the trunk) or in the form of *poikilodermic* (telangiectasia and depigmentation).
2. **Infiltration stage:** tumors with decaying ulcers are formed.
3. **Tumor stage:** tumors formed, some with a sunken cap - shaped surface (hence the name). Internal organs are also affected at this stage.

Manifestations are usually asymptomatic, but when the cutaneous nerves are affected **itching 'does not respond to antihistamines**.

## Clinical variants

- Folliculotropic MF
- Pagetoid reticulosis
- Granulomatous sagging skin
- Sézary's syndrome

Sézary's syndrome

**Sézary's syndrome** is a leukemic form of Mycosis fungoides along with erythroderma, generalized lymphadenopathy and hepatosplenomegaly. Clinically, there is red-purple discolouration of the skin, peeling of the entire skin, loss of nails and alopecia, and persistent itching.

## Histopathological picture

Epidermotropism and Pautrer's microabscesses in the epidermis.

## Therapy

Photochemotherapy (PUVA) for skin involvement only. Furthermore, applications of carmustine, corticoids and retinoids. Interferon  $\alpha$  is used in case of major exposure.

## Course and prognosis

Chronic course for decades. Prognosis according to the extent of disability.

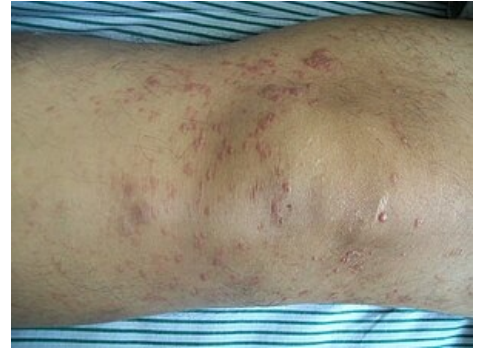## Links

### Related articles

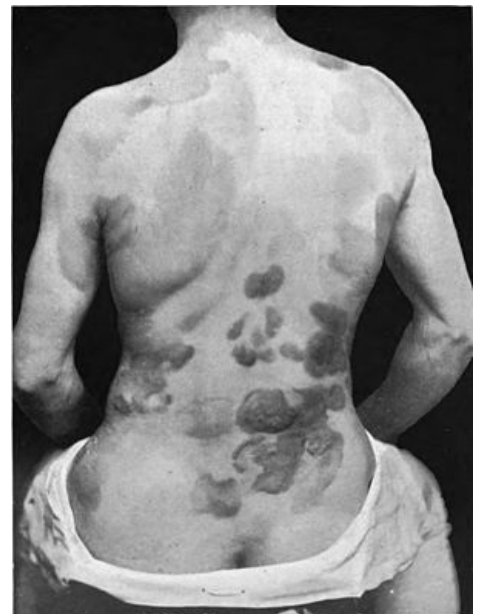
- Lymphoma
- Cutaneous lymphoma
- CNS lymphomas
- Hodgkin's lymphoma

## References

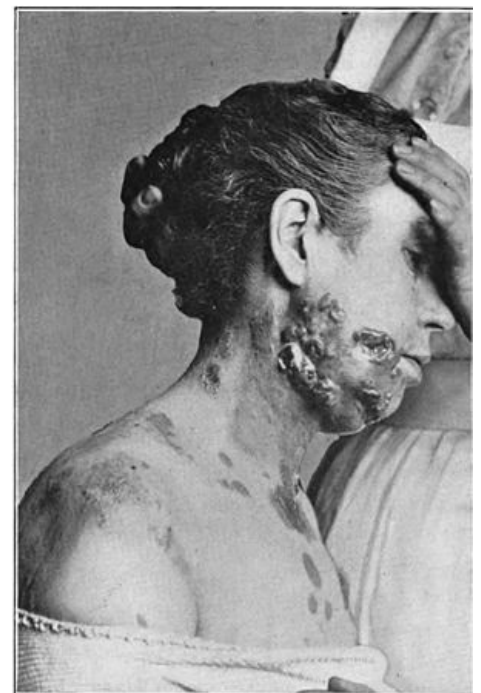
- ŠTORK, Jiří, et al. *Dermatovenerologie*. 1. edition. Prague : Galén, Karolinum, 2008. ISBN 978-80-7262-371-6.



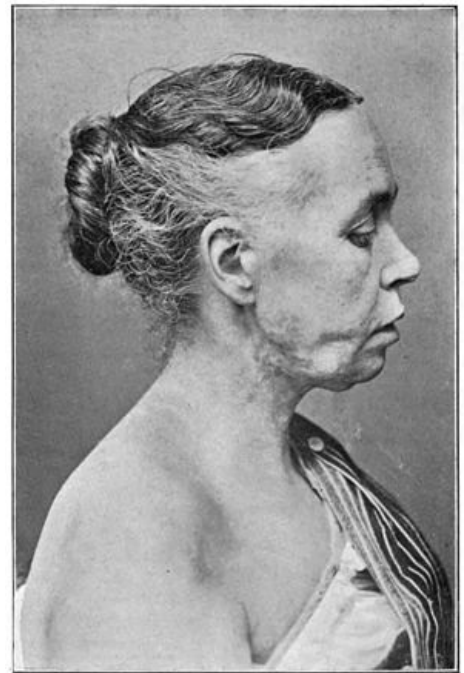Mycosis fungoides knee



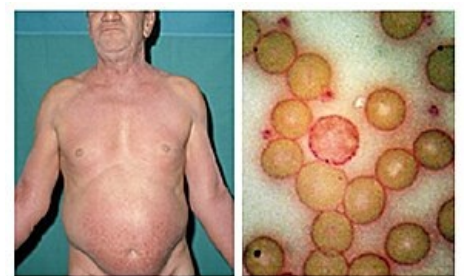Mycosis fungoides



Mycosis fungoides - June 1902



Mycosis fungoides – October 1902



Sézary's syndrome