

Musculus triceps brachii

Beginning:

caput longum - *tuberculum infraglenoidale scapulae*;

caput laterale - posterior surface of the humerus, proximal to the *sulcus nervi radialis*;

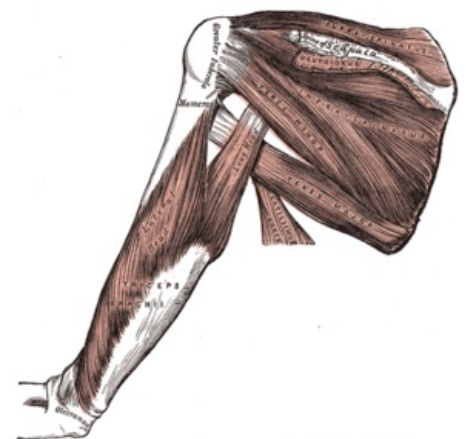
caput mediale - posterior surface of the humerus, distal to the *sulcus nervi radialis*.

Tendon: olecranon ulnae.

Innervation: *nervus radialis* (C6-C8).

Function: extension of the elbow joint; *caput longum* helps in dorsal flexion and adduction at the shoulder joint.

Vascular supply: *a. profunda brachii* (*caput longum*), *a. circumflexa humeri caudalis*, *a. subscapularis*, *a. collateralis radialis*, *a. circumflexa scapulae*, *a. collateralis ulnaris* (*caput mediale*).



Back muscles of arm.

References

- ČIHÁK, Radomír. *Anatomie 1*. 2. vydání. Praha : Grada, 2001. 497 s. ISBN 80-7169-970-5.