

# Musculus tibialis posterior

**Origin:** membrana interossea cruris, edges of the fibula and tibia

**Attachment:** tuberossitas ossis navicularis, the lower surface of the sphenoid bones

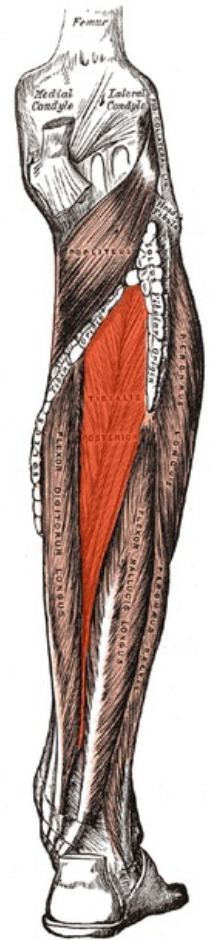
**Innervation:** n. tibialis (L<sub>5</sub>–S<sub>1-2</sub>)

**Function:** plantar flexion of the foot, support of the longitudinal arch of the foot

## Links

## References

- ČIHÁK, Radomír. *Anatomie 1*. 2. edition. Grada, 2001. 497 pp. ISBN 80-7169-970-5.
- VIGUÉ, Jordi. *Atlas lidského těla*. 3. edition. Rebo, 2007. ISBN 978-80-7234-881-7.



**Tibialis posterior muscle**