

Musculus teres minor

Beginning: *margo lateralis scapulae*.

Tendon: *tuberculum majus humeri*.

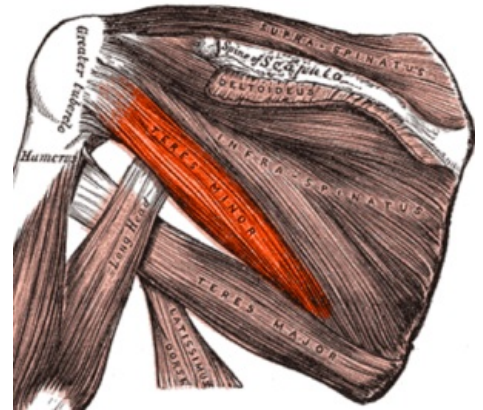
Innervation: *nervus axillaris* (C5).

Function: external rotation of the shoulder joint.

Vascular supply: *a. circumflexa humeri caudalis*

References

- ČIHÁK, Radomír a Miloš GRIM. *Anatomie*. 2., uprav. a dopl vydání. Praha : Grada Publishing, 2002. 470 s. sv. 1. ISBN 80-7169-970-5.



Teres minor, colorized.