

Musculus tensor fasciae latae

Origin: spina iliaca anterior superior, part of labium externum cristae iliacaе

Insertion: tractus iliotibialis

Inervation: nervus gluteus superior (z L₄-S₁)

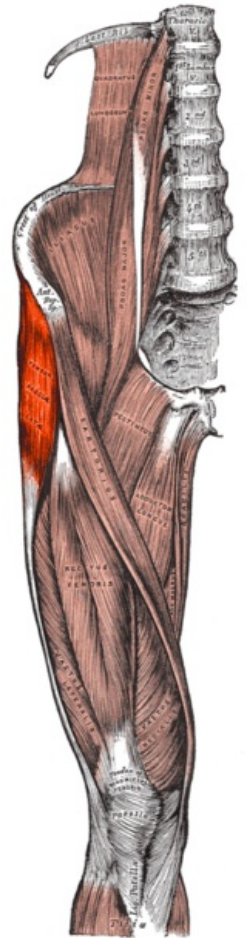
Function: flexion, abduction, internal rotation at the hip joint , maintains extension at the knee joint

Tractus iliotibialis : is a thickened tendon strip located on the lateral side of the thigh, to which *the tensor fasciae latae muscle* attaches from the front and *the gluteus maximus muscle* from the back . It descends to the knee joint and attaches to *the condylus lateralis tibiae* , maintains the stability of the knee, and also fixes the lumbar joint.

Links

References

- ČIHÁK, Radomír. *Anatomie 1*. 2. edition. Grada, 2001. 497 pp. ISBN 80-7169-970-5.
- VIGUÉ, Jordi. *Atlas lidského těla*. 3. edition. Rebo, 2007. ISBN 978-80-7234-881-7.



Tensor fasciae latae muscle