

Musculus subscapularis

Beginning: *facies anterior scapulae*.

Tendon: *tuberculum minus humeri*.

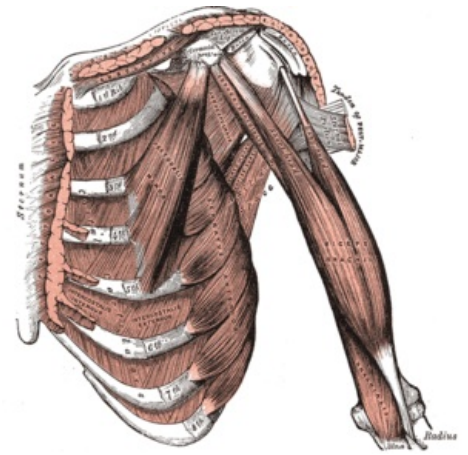
Innervation: *nervus subscapularis* (C5, C6).

Function: internal rotation of the humerus.

Vascular supply: *a. subscapularis, a. circumflexa scapulae*

References

- ČIHÁK, Radomír a Miloš GRIM. *Anatomie*. 2., uprav. a dopl vydání. Praha : Grada Publishing, 2002. 470 s. sv. 1. ISBN 80-7169-970-5.



Deep front muscles of arm.