

Musculus popliteus

Origin: lateral epicondyle of the femur

Attachment: posterior surface of the proximal part of the tibia

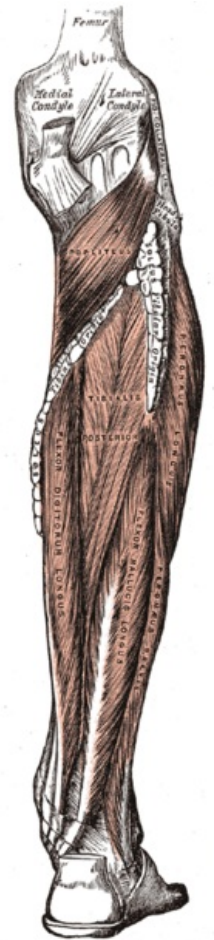
Innervation: n. tibialis (L_4-S_1)

Function: knee flexion, lower leg internal rotation

Links

References

- ČIHÁK, Radomír – GRIM, Miloš. *Anatomie*. 2., uprav. a dopl edition. Grada Publishing, 2002. 470 pp. vol. 1. ISBN 80-7169-970-5.
- VIGUÉ, Jordi. *Atlas lidského těla*. 3. edition. Rebo, 2007. ISBN 978-80-7234-881-7.



Popliteus
muscle