

# Musculus plantaris

**Origin:** facies poplitea femoris

**Attachment:** tuber calcanei (the attachment merges with the tendo calcanei)

**Innervation:** n. tibialis

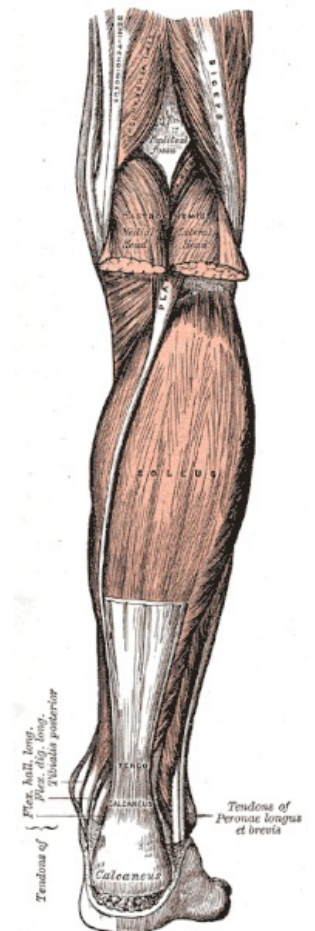
**Function:**

1. knee joint – auxiliary flexion;
2. foot – weak plantar flexion.

## Links

## References

- ČIHÁK, Radomír – GRIM, Miloš. *Anatomie*. 2., uprav. a dopl edition. Grada Publishing, 2002. 470 pp. vol. 1. ISBN 80-7169-970-5.
- VIGUÉ, Jordi. *Atlas lidského těla*. 3. edition. Rebo, 2007. ISBN 978-80-7234-881-7.



### Plantaris muscle