

Musculus piriformis

Origin: Front surface of os sacrum, lateral edges of *foramina sacralia anteriora*.

Insertion: Trochanter major femoris.

Inervation: plexus sacralis (L₄– S_{1–2}).

Function: External rotation in the hip joint , then extension, abduction in the hip joint, divides *the foramen ischiadicum majus* .

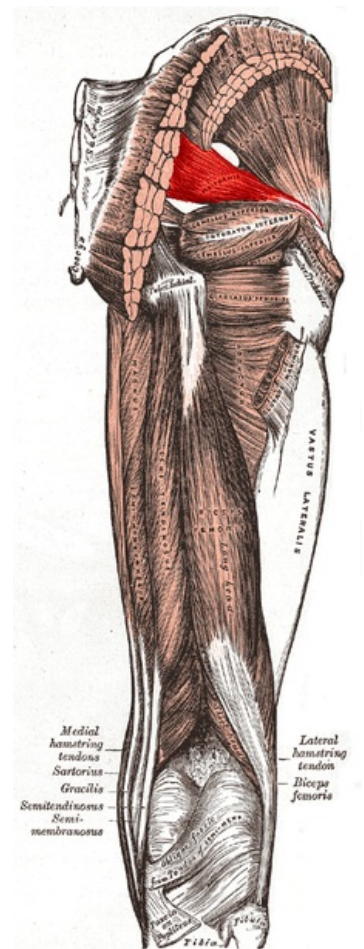
Links

Related articles

- Foramen suprapiriforme
- Foramen infrapiriforme

References

- ČIHÁK, Radomír. *Anatomie 1*. 2. edition. Grada, 2001. 497 pp. ISBN 80-7169-970-5.
- VIGUÉ, Jordi. *Atlas lidského těla*. 3. edition. Rebo, 2007. 164 pp. ISBN 978-80-7234-881-7.



Piriformis muscle