

# Musculus palmaris brevis

**Musculus palmaris brevis** is a small subcutaneous muscle that runs along the entire hypothenar.

## Beginning:

- ulnar edge of the palmar aponeurosis.

## Attachment:

- skin.

## Innervation:

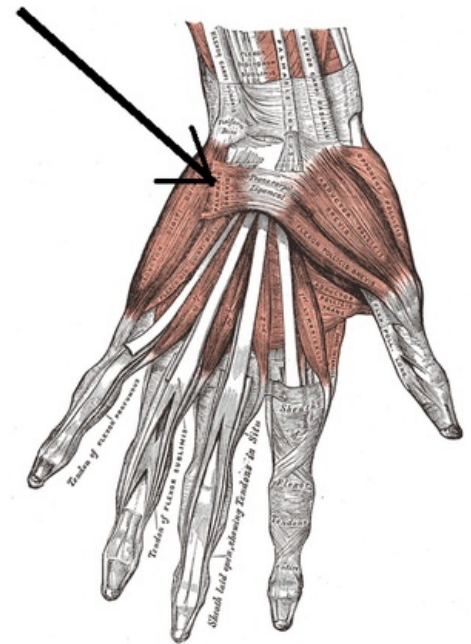
- nervus ulnaris (ramus superficialis). <sup>[1]</sup>

**Note: Musculus palmaris brevis** is the only muscle that is innervated by the ramus superficialis nervus ulnaris.

## Links

## References

- ČIHÁK, Radomír. *Anatomy 1. 2.* edition. Prague : Grada, 2001. 497 pp. ISBN 80-7169-970-5.
- 1. PETROVICKY, Pavel. *Anatomy with Topography and Clinical Applications III.. 1.* edition. Martin : Osveta, 2002. 542 pp. pp. 78. ISBN 80-8063-048-8.



Musculus palmaris brevis