

Musculus levator labii alaeque nasi

Template:Infobox - Muscle

Beginning: *processus frontalis maxillae*.

Attachment: skin in the area of the nasal wing; lateral edge of the upper lip.

Innervation: *n. facialis*.

Function:

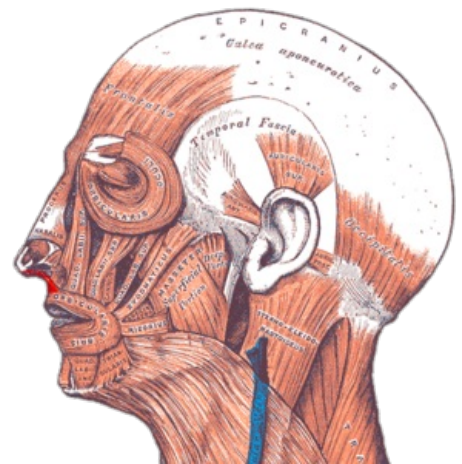
- flattens *sulcus nasolabialis*;
- pulls the upper lip cranially;
- enlarges the nostrils.

Links

Used literature

- ČIHÁK, Radomír – GRIM, Miloš. *Anatomie*. 2. edition. Praha : Grada Publishing, 2002. 470 pp. vol. 1. ISBN 80-7169-970-5.
- HUDÁK, Radovan – KACHLÍK, David, et al. *Memorix anatomie*. 2. edition. Praha : Triton, 2013. ISBN 978-80-7387-712-5.

Template:Navbox - Head of the muscles



Gray — musculus levator labii superioris alaeque nasi