

Musculus flexor pollicis longus

Beginning: the front face of the radio.

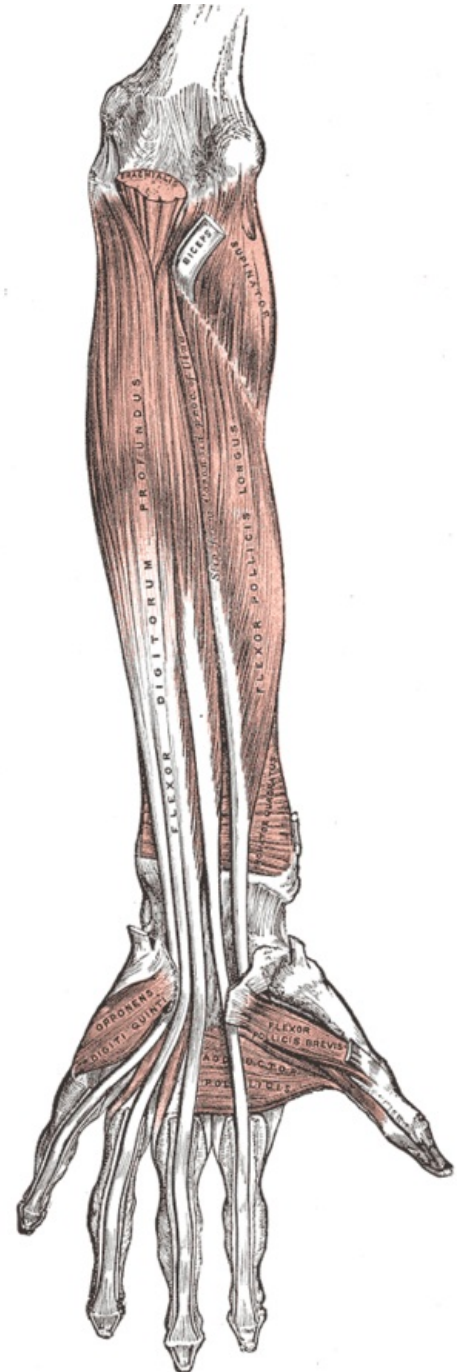
Tendon: base of the end link of the thumb.

Innervation: *nervus medianus* (C6 and C7).

Function: flexion at the interphalangeal joint of the thumb.

References

- ČIHÁK, Radomír a Miloš GRIM. *Anatomie*. 2., uprav. a dopl vydání. Praha : Grada Publishing, 2002. 470 s. sv. 1. ISBN 80-7169-970-5.



Musculus flexor pollicis longus.