

Musculus flexor pollicis brevis

Musculus flexor pollicis brevis has two heads: **caput superficiale** and **caput profundum**.

The beginning:

- *carpal bones - os capitatum, os trapezoideum and ligg. intercarpalia palmaria (caput profundum)*
- *retinaculum musculorum flexorum and tuberculum ossis trapezii (caput superficiale)*

Extension:

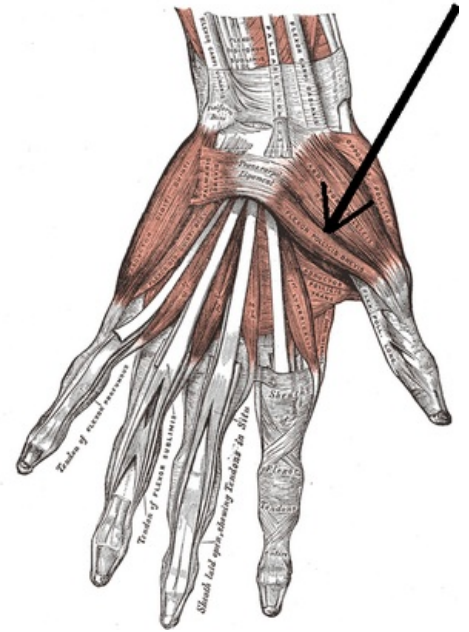
- Lateral base of the proximal phalanx of the thumb;
- sesamoid bone of the thumb (radial).

Innervation:

- *caput superficiale: nervus medianus;*
- *caput profundum: nervus ulnaris.*

Function:

- Flexion of the metacarpophalangeal joint of the thumb;
- partial abduction of the thumb;
- partial opposition of the thumb.



Musculus flexor pollicis brevis.

References

- ČIHÁK, Radomír. *Anatomie 1*. 2. vydání. Praha : Grada, 2001. 497 s. ISBN 80-7169-970-5.