

Musculus flexor hallucis longus

Origin: lower part of the back of the fibula, adjacent membrane interossea cruris

Attachment: plantar side of the distal phalanx of the thumb

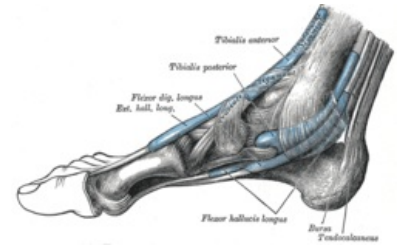
Innervation: n. tibialis (L₅–S₂)

Function: thumb flexion, auxiliary plantar flexion of the foot

Links

References

- ČIHÁK, Radomír. *Anatomie 1*. 2. edition. Grada, 2001. 497 pp. ISBN 80-7169-970-5.
- VIGUÉ, Jordi. *Atlas lidského těla*. 3. edition. Rebo, 2007. ISBN 978-80-7234-881-7.



Flexor hallucis longus muscle