

Musculus flexor digitorum superficialis

Beginning:

- *caput humeroulnare* - *caput commune ulnare* below the epicondyle of the humerus and on the *lig. collaterale ulnare* of the elbow joint and partly on the ulna;
- *caput radiale* - on the radius, along the attachment of the *m. supinator*.

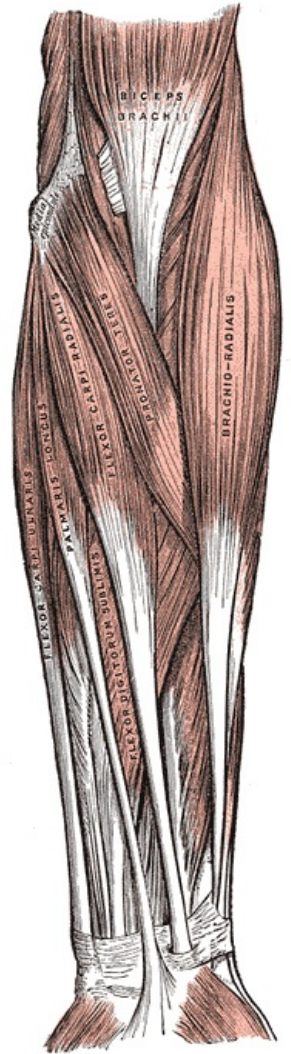
Extension: each of the four tendons bifurcates (chiasma tendinum) at the base of the middle link of the finger.

Innervation: *nervus medianus* (C7-Th1).

Function: flexion of the proximal interphalangeal joints of the fingers.

References

- ČIHÁK, Radomír a Miloš GRIM. *Anatomie*. 2., uprav. a dopl vydání. Praha : Grada Publishing, 2002. 470 s. sv. 1. ISBN 80-7169-970-5.



Superficial muscles of front of of forearm.