

Musculus flexor digiti minimi brevis (hand)

Beginning: eminentia carpi ulnaris, retinaculum musculorum flexorum

Attachment: the base of the proximal joint of the 5th finger

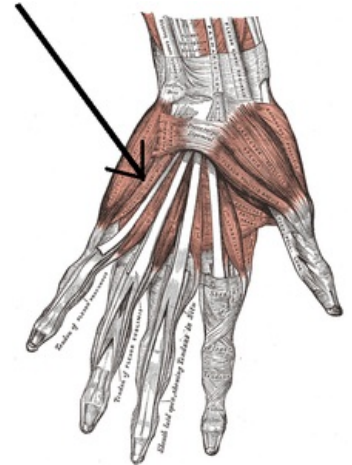
Innervation: nervus ulnaris (via r. profundus) (C8–Th1)

Function: flexion of the little finger

Links

References

- ČIHÁK, Radomír. *Anatomy 1*. 2. edition. Prague : Grada, 2001. 497 pp. ISBN 80-7169-970-5.



Musculus flexor digiti minimi brevis