

Musculus fibularis longus

Origin: the upper half of the fibula.

Attachment: plantar side of os cuneiforme mediale, base of thumb metatarsus.

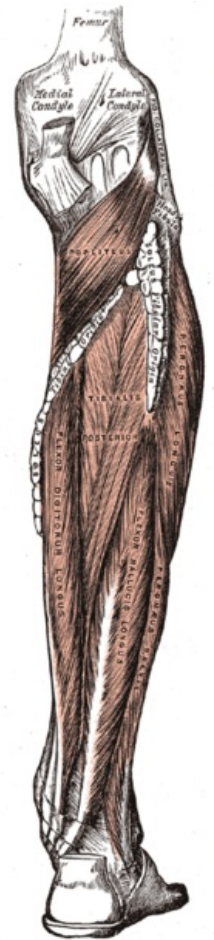
Innervation: n. fibularis superficialis.

Function: pronation, abduction, plantar flexion (maintains the transverse arch of the foot).

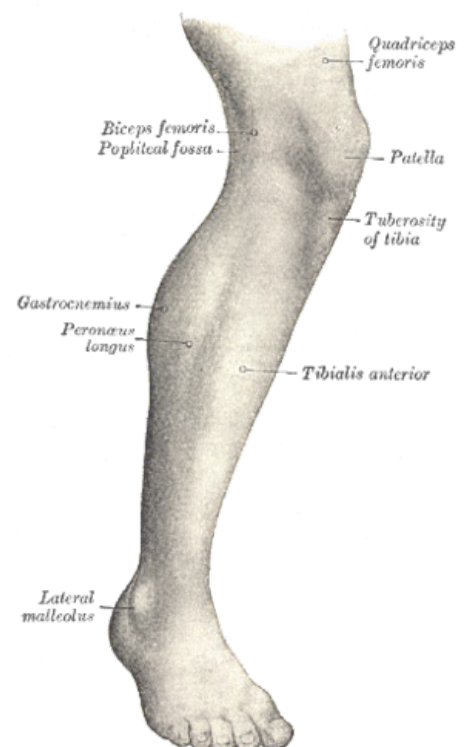
Links

References

- ČIHÁK, Radomír. *Anatomie 1*. 2. edition. Grada, 2001. 497 pp. ISBN 80-7169-970-5.
- VIGUÉ, Jordi. *Atlas lidského těla*. 3. edition. Rebo, 2007. ISBN 978-80-7234-881-7.



Fibularis longus muscle



M. fibularis longus (pictured on the left as the peroneus longus muscle)