

Musculus fibularis brevis

Origin: lower surface of the fibula

Attachment: tuberosity of the fifth metatarsal

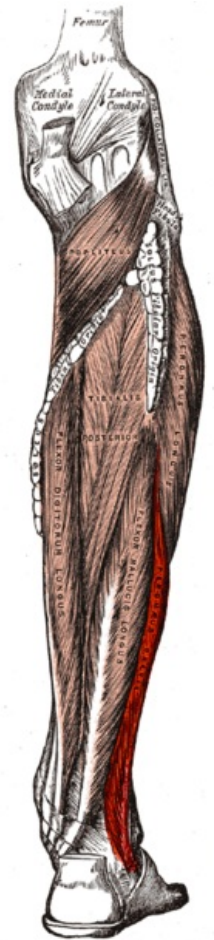
Innervation: n. fibularis superficialis

Function: pronation, abduction, plantar flexion

Links

References

- ČIHÁK, Radomír. *Anatomie 1*. 2. edition. Grada, 2001. 497 pp. ISBN 80-7169-970-5.
- VIGUÉ, Jordi. *Atlas lidského těla*. 3. edition. Rebo, 2007. ISBN 978-80-7234-881-7.



Fibularis brevis muscle