

Musculus extensor pollicis brevis

Beginning: *radius*.

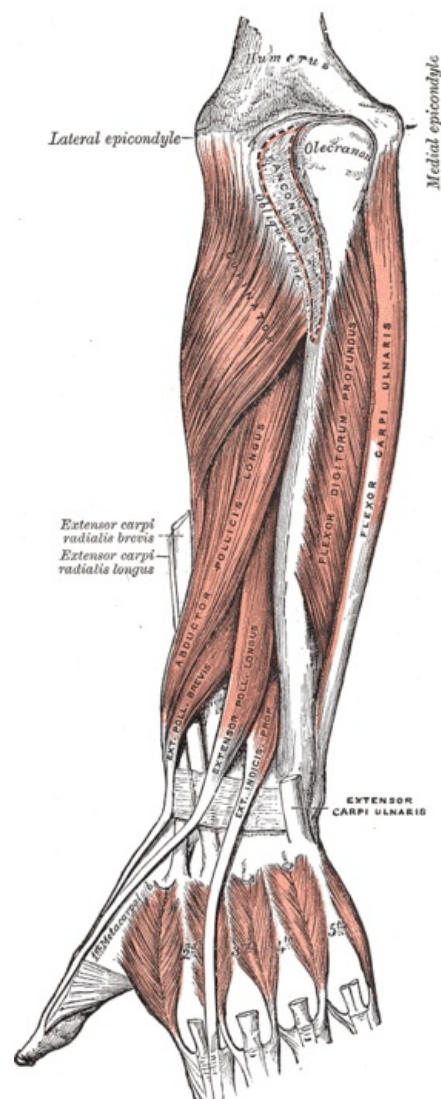
Extension: dorsal surface of the proximal *phalanx* of the thumb.

Innervation: *nervus radialis* (C6-C8).

Function: extensor in the metacarpophalangeal joint of the thumb.

References

- ČIHÁK, Radomír a Miloš GRIM. *Anatomie*. 2., uprav. a dopl. vydání. Praha : Grada Publishing, 2002. 470 s. sv. 1. ISBN 80-7169-970-5.



Musculus extensor pollicis brevis.