

Musculus extensor hallucis longus

Origin: medial surface of the fibula, membrana interossea cruris.

Attachment: distal joint of the thumb.

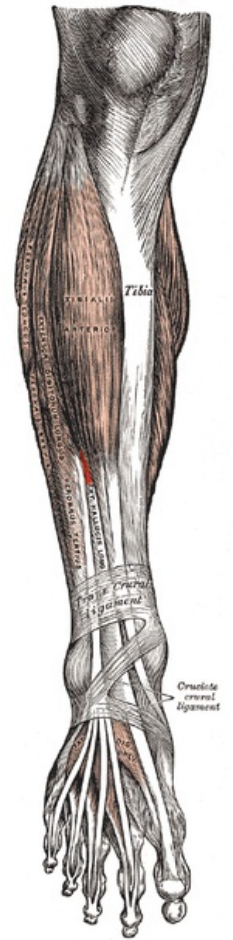
Innervation: n. fibularis profundus (L₄–S₁).

Function: thumb extension, foot dorsiflexion.

Links

References

- ČIHÁK, Radomír – GRIM, Miloš. *Anatomie*. 2., uprav. a dopl edition. Grada Publishing, 2002. 470 pp. vol. 1. ISBN 80-7169-970-5.
- VIGUÉ, Jordi. *Atlas lidského těla*. 3. edition. Rebo, 2007. ISBN 978-80-7234-881-7.



Extensor hallucis longus muscle