

Musculus biceps brachii

Beginning:

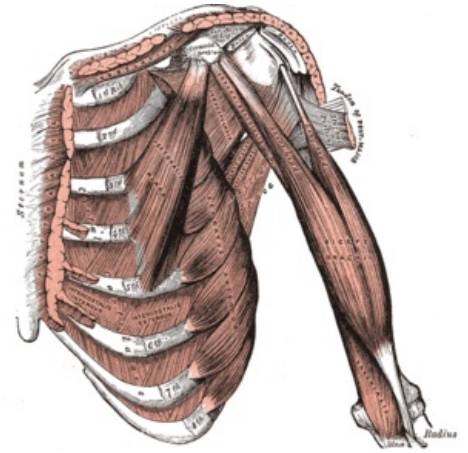
- caput longum - *tuberculum supraglenoidale scapulae*;
- caput breve - *processus coracoideus scapulae*.

Tendon: *tuberositas radii* (main tendon), secondary tendon - *aponeurosis musculi bicipitis brachii* (lacertus fibrosus).

Innervation: *nervus musculocutaneus* (C5 and C6).

Functions: in the elbow joint, the whole muscle flexes and supinates; in the shoulder joint - the long head helps in abduction; the short head helps in adduction and ventral flexion.

Vascular supply: *a. brachialis*



Deep front muscles of arm.

References

- ČIHÁK, Radomír. *Anatomie 1*. 2. vydání. Praha : Grada, 2001. 497 s. ISBN 80-7169-970-5.