

Musculus adductor pollicis

Musculus adductor pollicis has two heads: **caput obliquum** and **caput transversum**.

The beginning:

- **caput obliquum**: bases of 2nd and 3rd metacarpus, *os trapezoideum*, *os capitatum*;
- **caput transversum**: 3rd metacarpus.

Extension:

- Capsule of metacarpophalangeal joint of thumb;
- sesamoid bone of the thumb (ulnar).

Innervation:

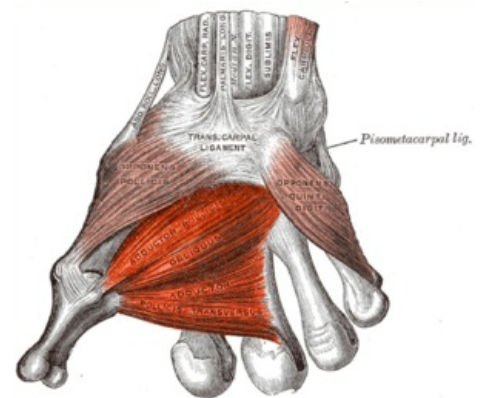
- *Ulnaris nerve (ramus profundus)*.

Function:

- Adduction of the thumb.

References

- ČIHÁK, Radomír. *Anatomie 1*. 2. vydání. Praha : Grada, 2001. 497 s. ISBN 80-7169-970-5.



Musculus adductor pollicis.