

# Musculus abductor pollicis brevis

## Beginning:

- *tuberculum ossis scaphoidei*;
- *retinaculum musculorum flexorum*.

## Tendon:

- Base of proximal article of thumb;
- sesamoid bone of thumb (radial).

## Innervation:

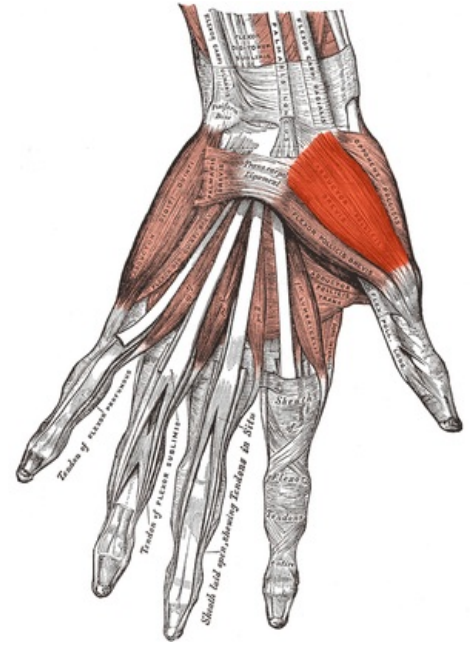
- *nervus medianus*.

## Function:

- Abduction of the thumb (like the musculus abductor pollicis longus).

## References

- ČIHÁK, Radomír. *Anatomie 1*. 2. vydání. Praha : Grada, 2001. 497 s. ISBN 80-7169-970-5.



Musculus abductor pollicis brevis.