

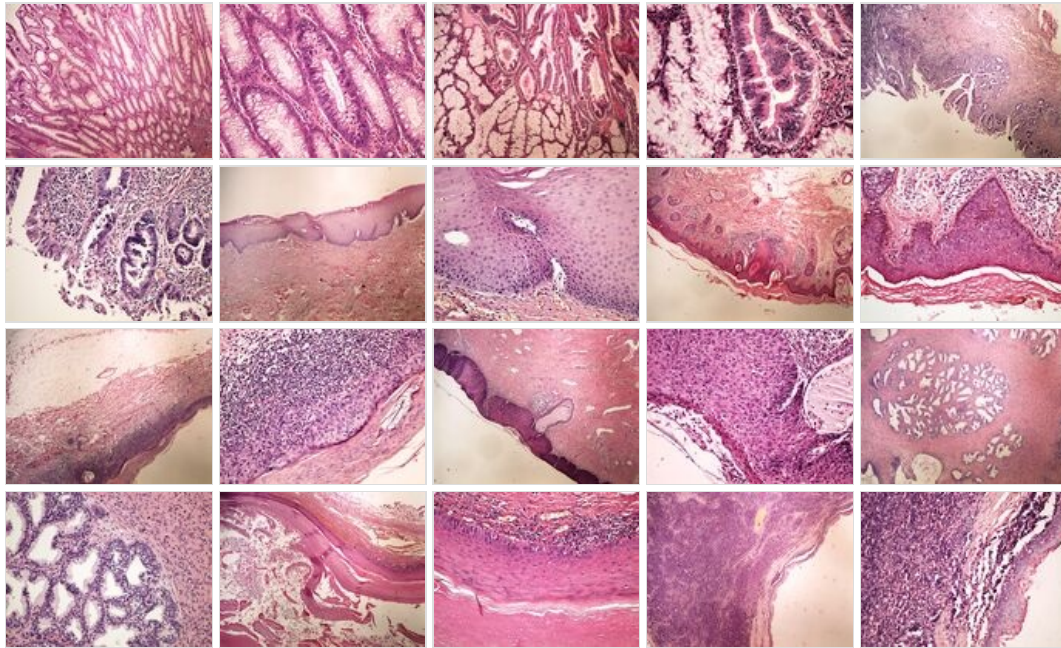
# Module GFPP - Practice no. 9

## Under construction / Forgotten

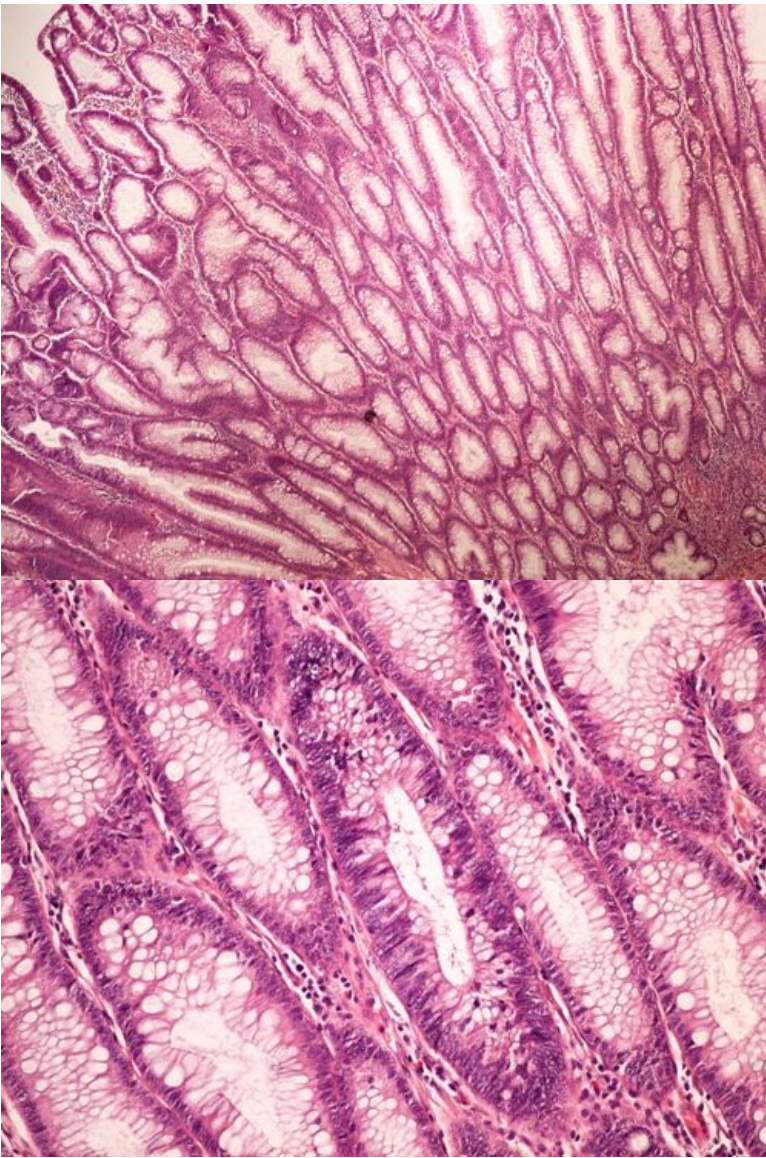
**This article was marked by its author as *Under construction*, but the last edit is older than 30 days.** If you want to edit this page, please try to contact its author first (you will find him in the history ([https://www.wikilectures.eu/index.php?title=Module\\_GFPP\\_-\\_Practice\\_no.\\_9&action=history](https://www.wikilectures.eu/index.php?title=Module_GFPP_-_Practice_no._9&action=history))). Watch the page as well. If the author will not continue in work, remove the template {{Under construction}} and the page.

Last update: Monday, 08 Dec 2014 at 5.30 pm.

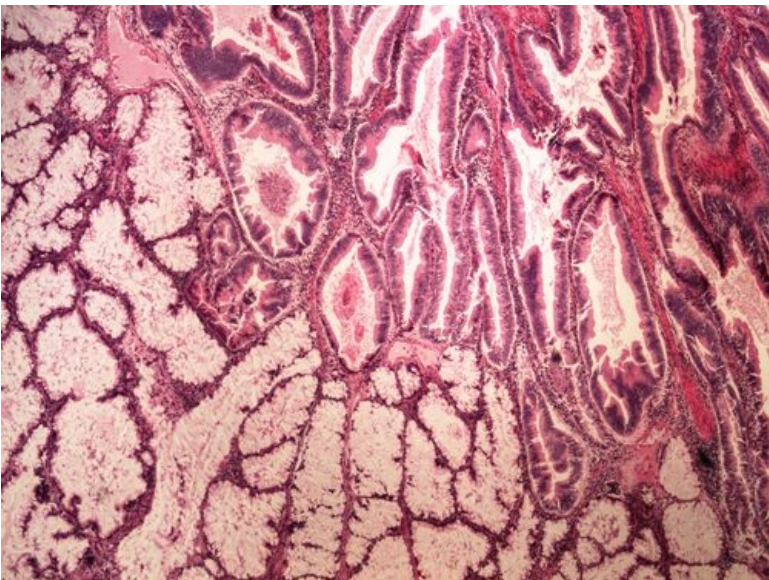
### Summary



**Slide no.1 and no.2 - tubulovilósní adenom tlustého střeva**



**Slide no.3 and no.4 - kancerisovaný adenom tlustého střeva**



File:Z 10-12 invasive cancer arising in adenoma

kancerisovany adenom tlusteho streva 20x oznaceno.jpg

**Slide no.5 and no.6 - DALM** [\[Expand\]](#)

File:Z 10-19 DALM 4x oznaceno.jpg File:Z 10-19 DALM 20x oznaceno.jpg

**Slide no.7 and no.8 - leukoplakie** [\[Expand\]](#)

File:Z 10-20 leukoplakia 4x oznaceno.jpg File:Z 10-20 leukoplakia 20x oznaceno.jpg



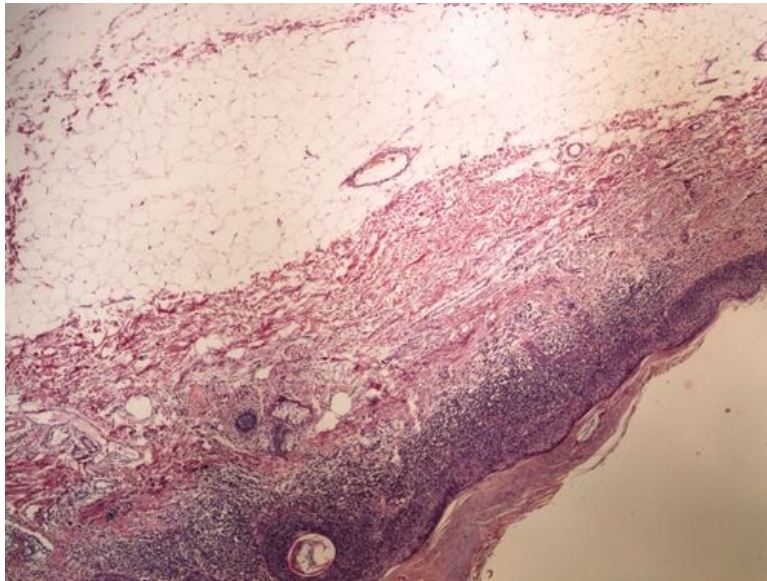
## Slide no.9 and no.10 - aktinická keratosa

[Expand]

File:Z 10-3 actinic keratosis aktinicka keratosa 4x oznaceno.jpg File:Z 10-3 actinic keratosis aktinicka keratosa 20x oznaceno.jpg

## Slide no.11 and no.12 - Bowenova dermatosa

[Expand]



File:Z 10-4 Bowen disease Bowenova dermatosa 20x

oznaceno.jpg

## Slide no.13 and no.14 - CIN

[Expand]

File:Z 10-5 CIN 4x oznaceno.jpg File:Z 10-5 CIN 20x oznaceno.jpg

## Slide no.15 and no.16 - hyperplasie prostaty

[Expand]

File:Z 8-2 prostate hyperplasia hyperplasie prostaty 4x oznaceno.jpg File:Z 8-2 prostate hyperplasia hyperplasie prostaty 20x oznaceno.jpg

## Slide no.17 and no.18- epidermoidní cysta

[Expand]

File:Z 8-3 epidermoid cyst epidermoidni cysta 4x oznaceno.jpg File:Z 8-3 epidermoid cyst epidermoidni cysta 20x oznaceno.jpg

## Slide no.19 and no.20 - branchiogenní cysta

[Expand]

File:Z 8-4 branchial cleft cyst branchiogenni cysta 4x oznaceno.jpg File:Z 8-4 branchial cleft cyst branchiogenni cysta 20x oznaceno.jpg

## Odkazy

[Expand]

## Navigace