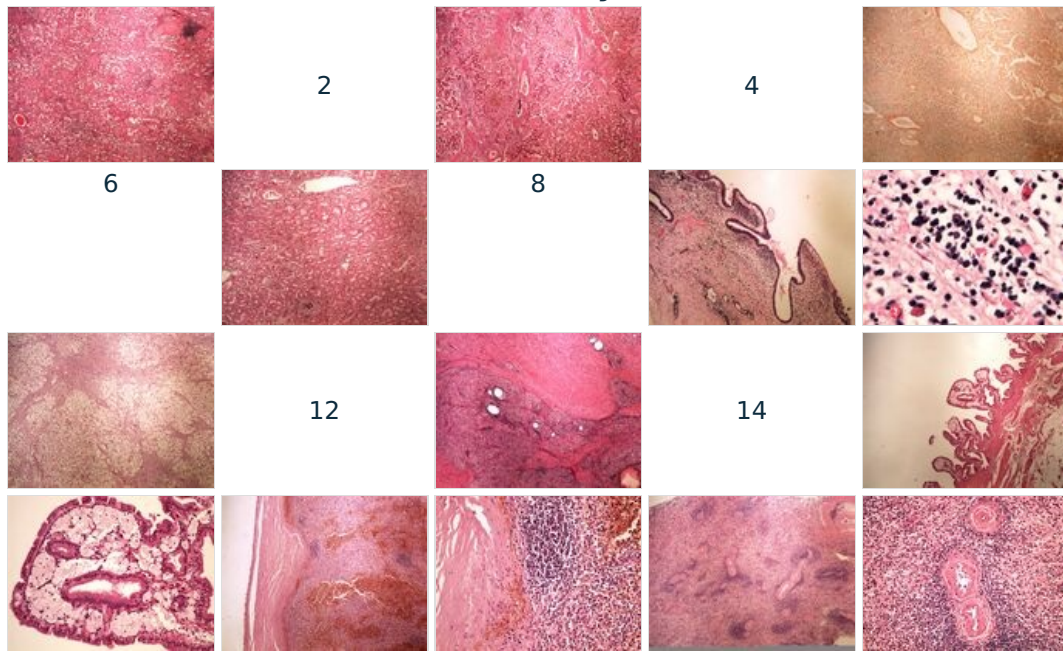
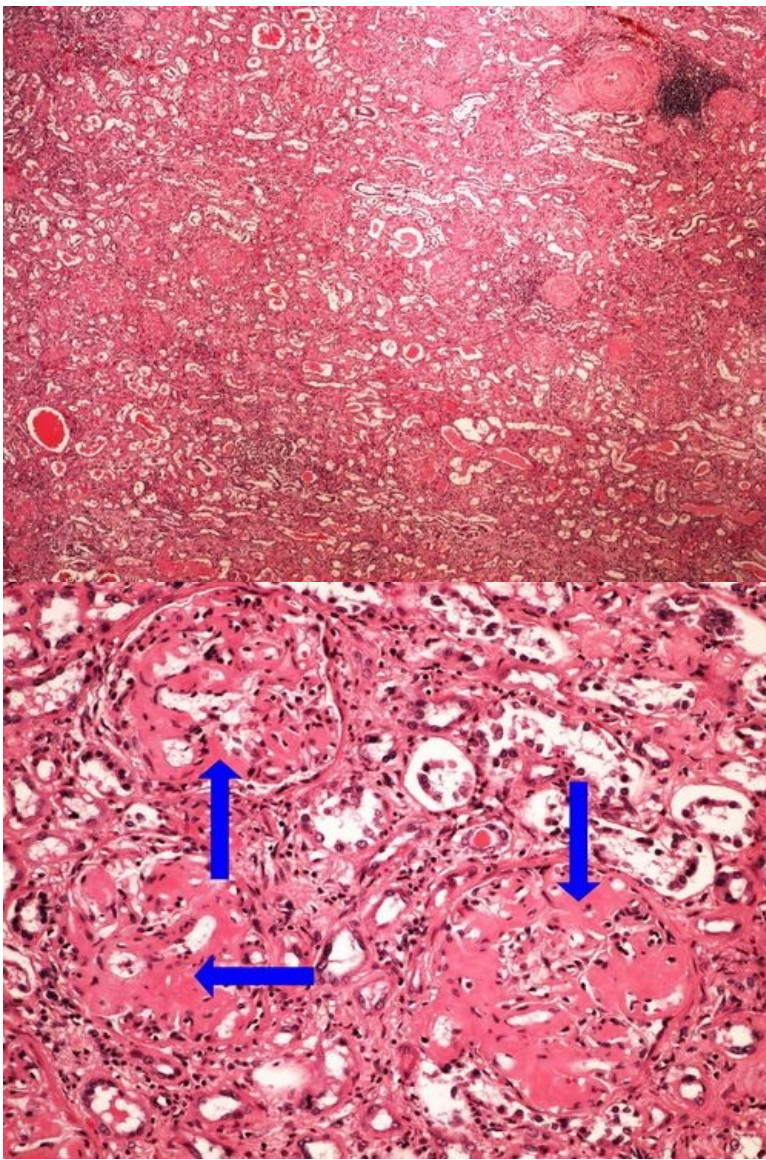


Module GFPP - Practice no. 3

Summary



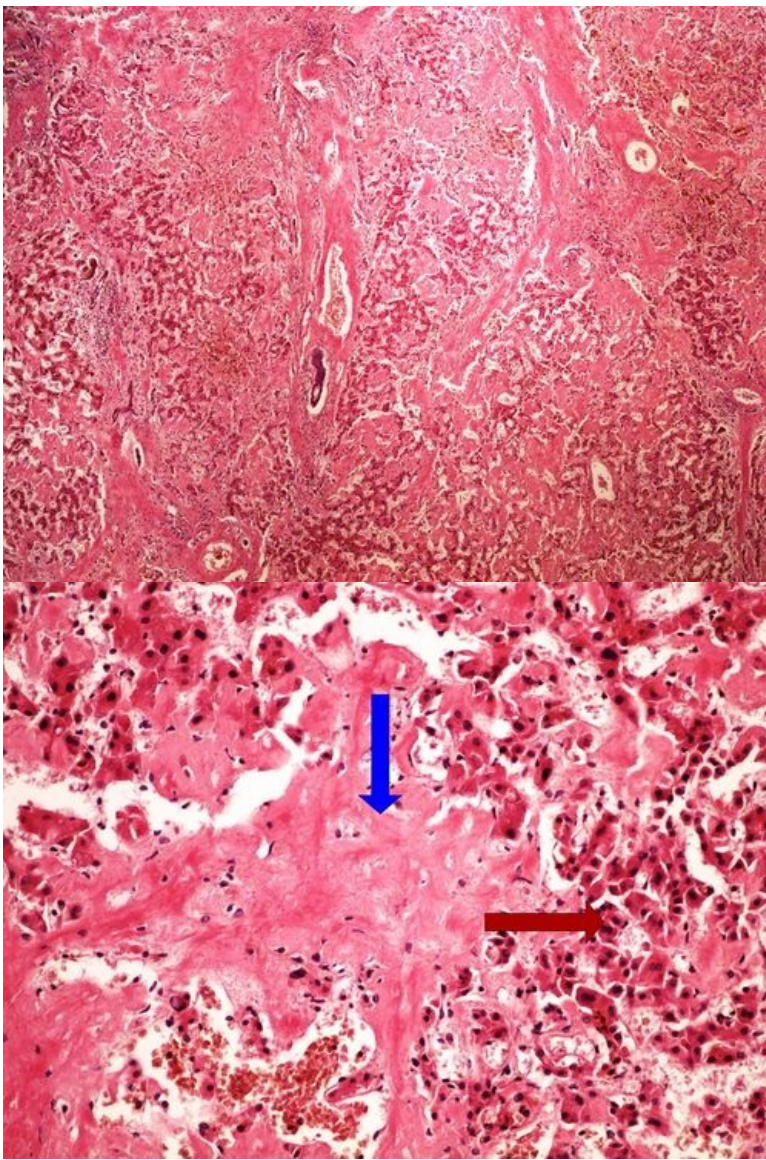
Slide no.1 and no.2 - amyloidóza ledviny (HE)



Structures to know

[Expand]

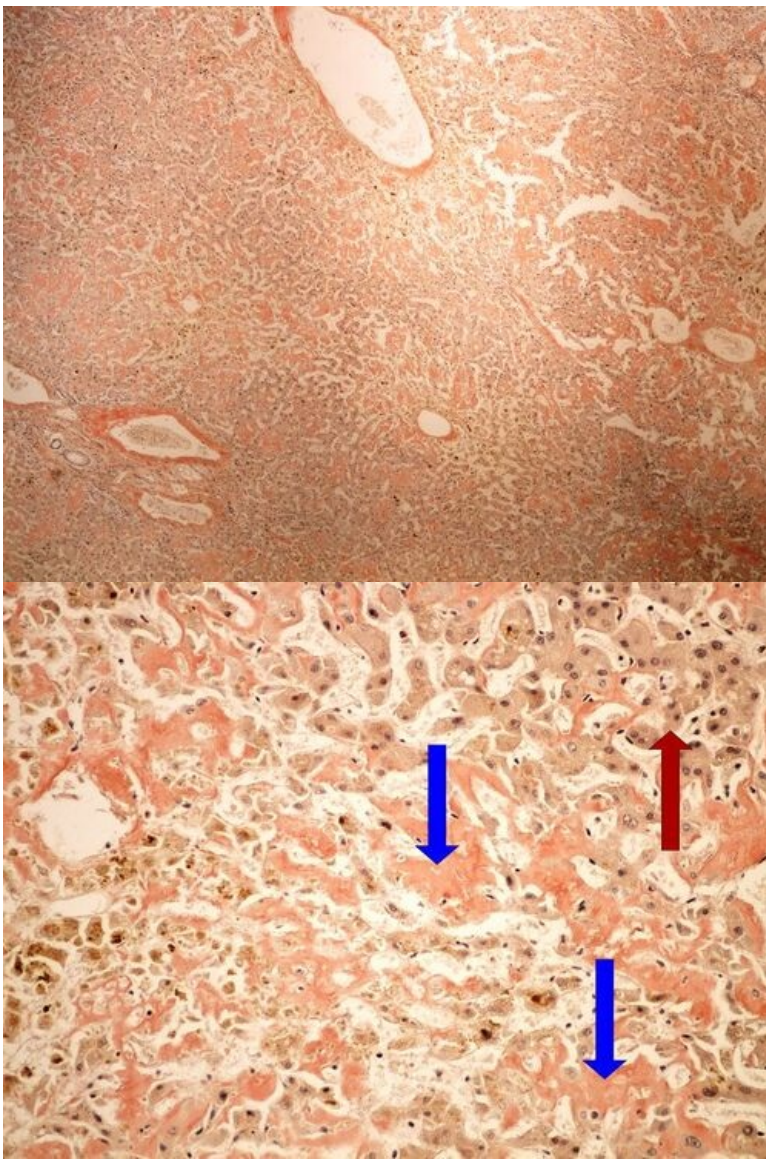
Slide no.3 and no.4 - amyloidóza jater (HE)



Structures to know

[Expand]

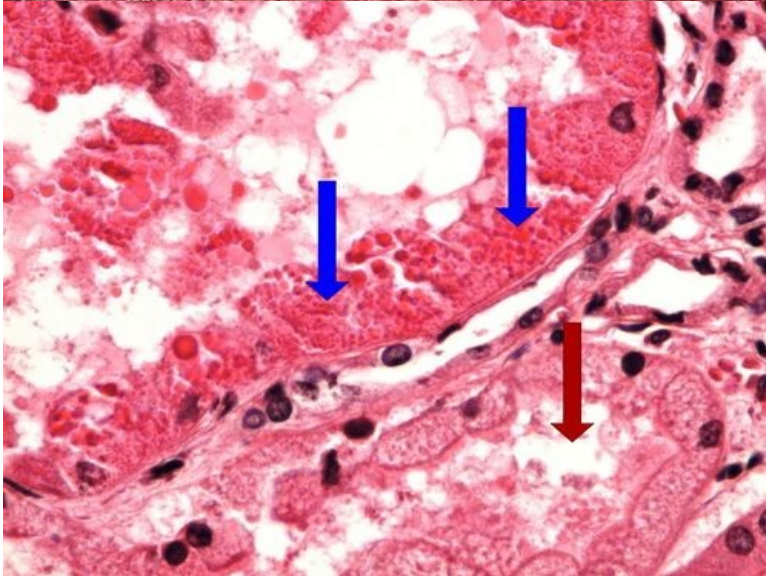
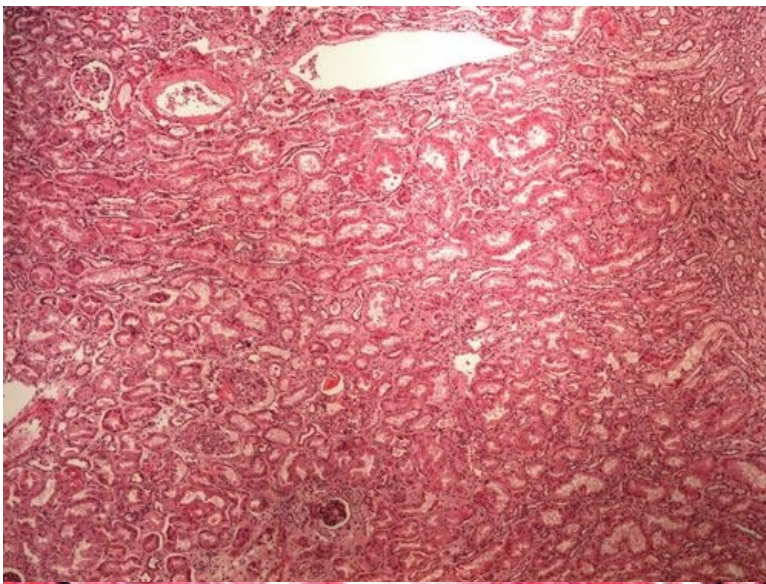
Slide no.5 and no.6 - amyloidóza jater (kongo červen)



Structures to know

[Expand]

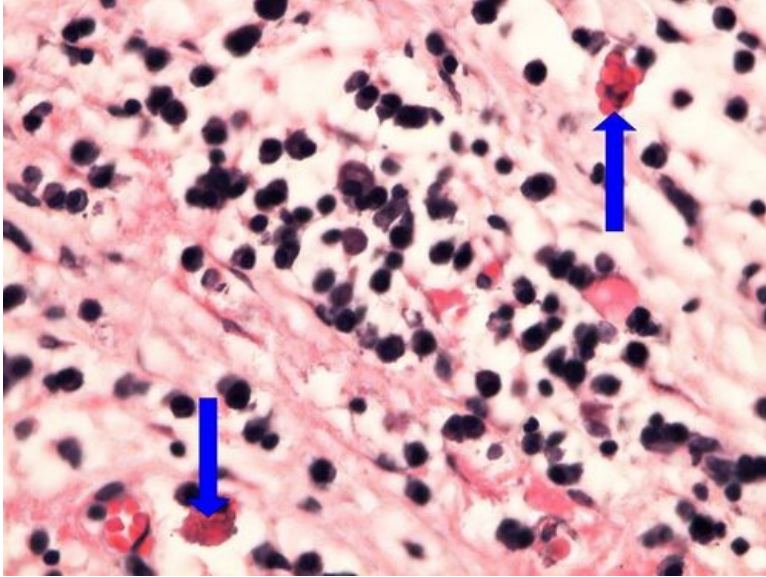
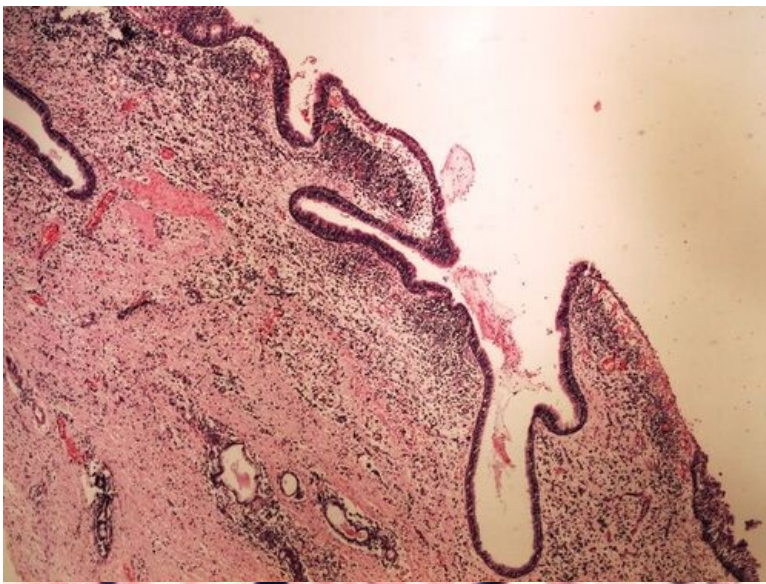
Slide no.7 and no.8 - hyalinní zkapénkovatění ledviny



Structures to know

[\[Expand\]](#)

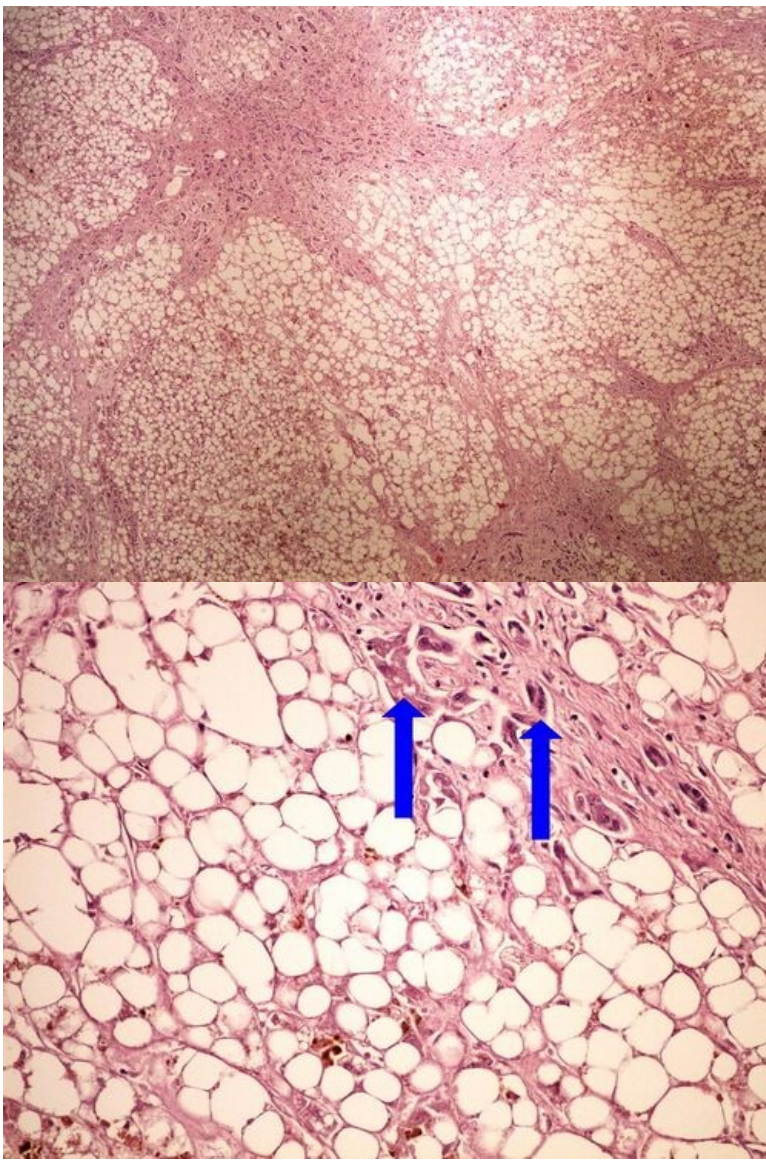
Slide no.9 and no.10 - Russelova tělíska



Structures to know

[\[Expand\]](#)

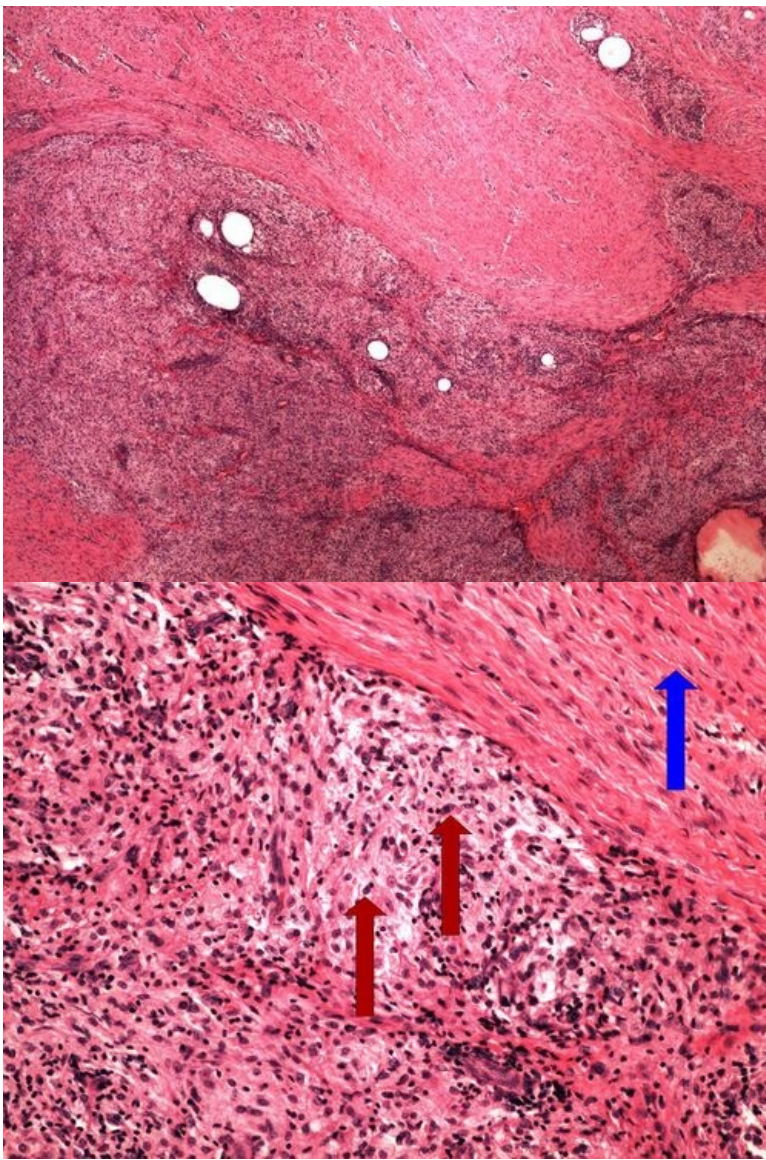
Slide no.11 and no.12 - steatosa jater



Structures to know

[Expand]

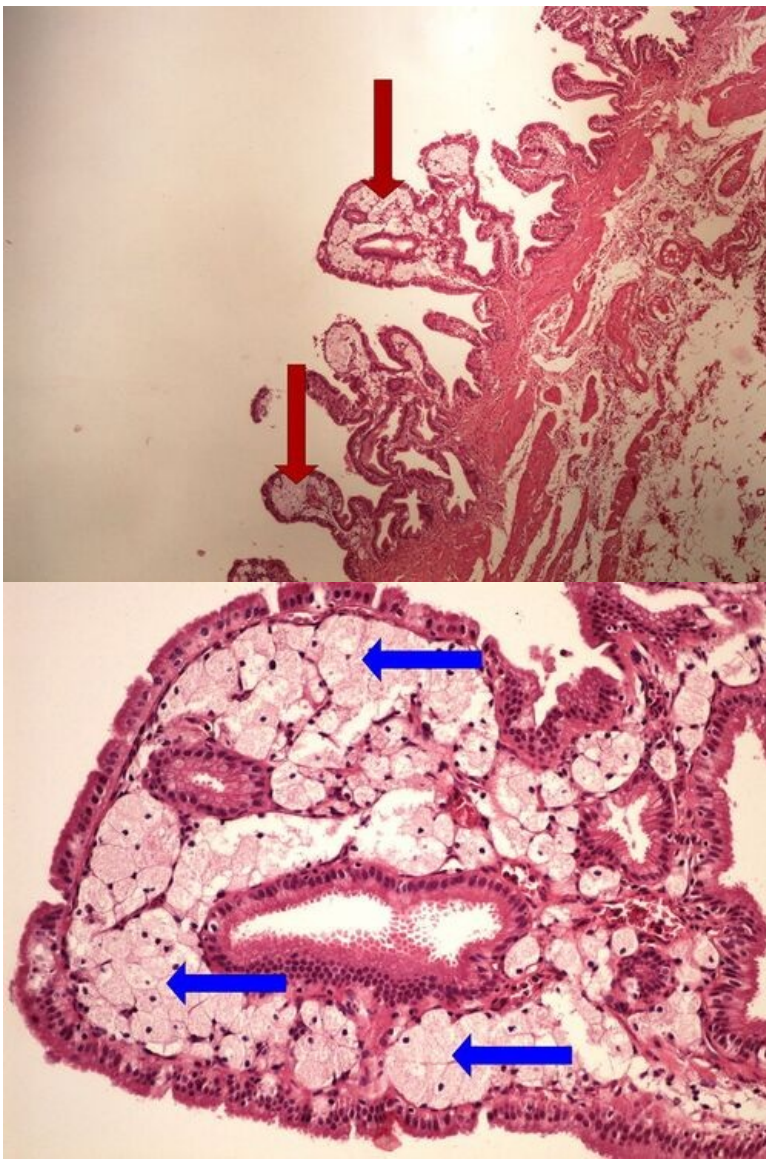
Slide no.13 and no.14 - zánětlivý pseudoxantom



Structures to know

[Expand]

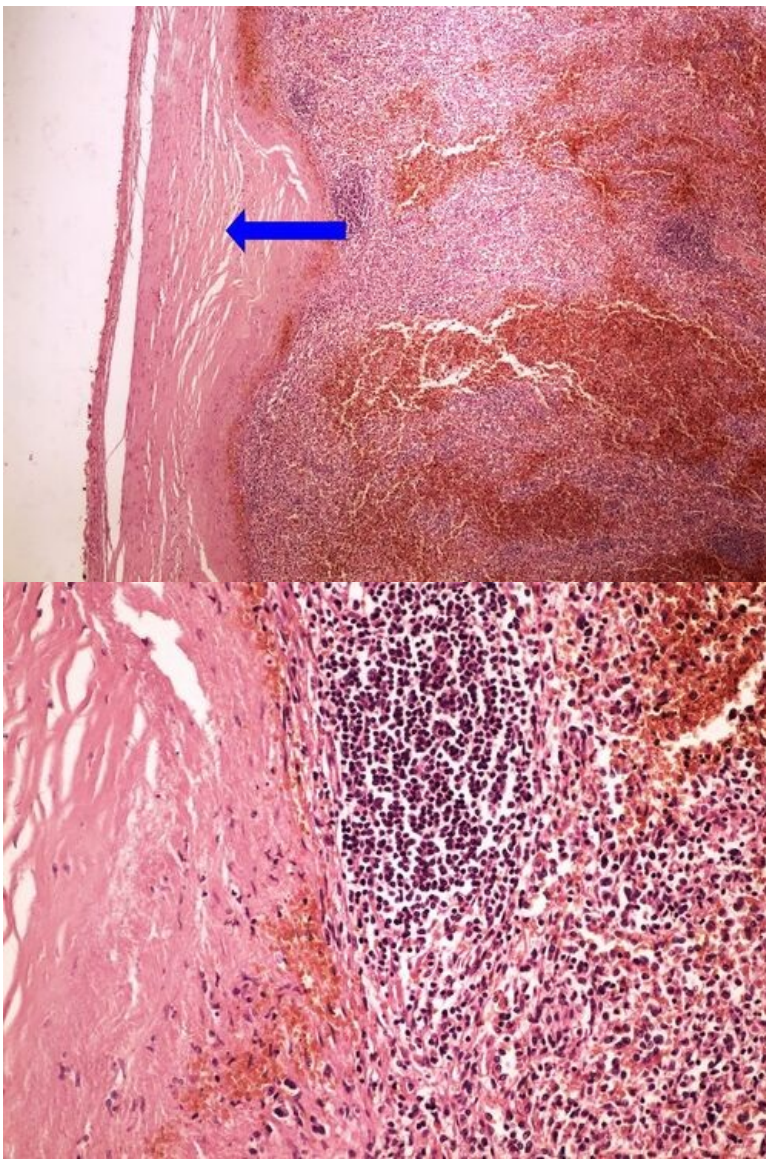
Slide no.15 and no.16 - cholesterolosa žlučníku



Structures to know

[Expand]

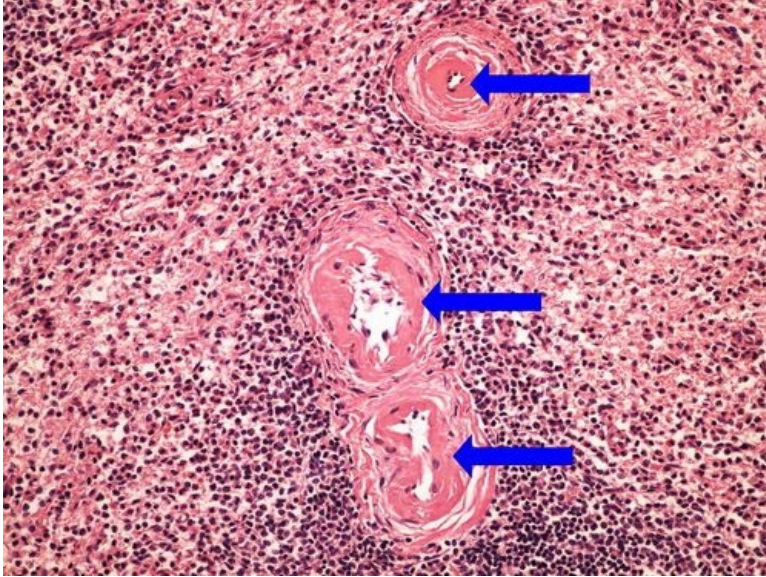
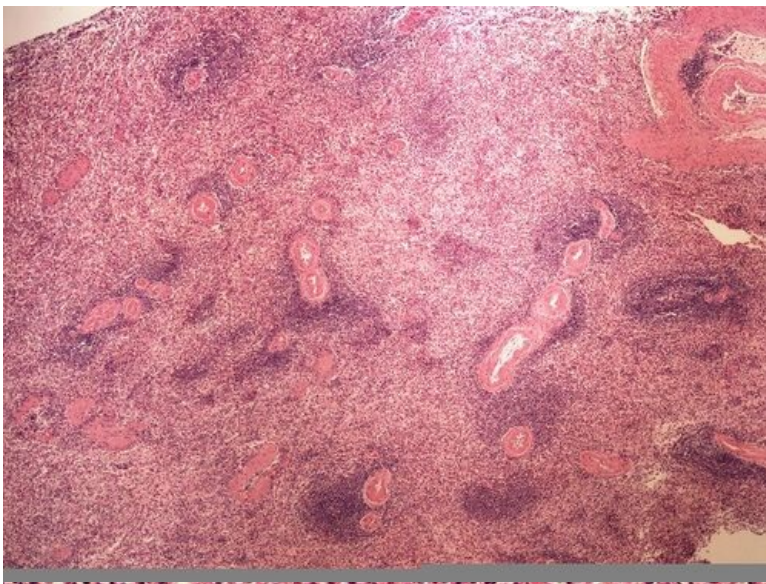
Slide no.17 and no.18 - perisplenitis cartilaginea



Struktury

[Expand]

Slide no.19 and no.20 - fibrinodní dystrofie



Structures to know

[\[Expand\]](#)

Odkazy

Navigace

[← Practice no. 2](#)

[Module GFPP \(3. LF UK\)](#)

[Practice no. 4 →](#)