

Mastoiditis

This is an inflammatory disease of the sockets **of the mastoid process** of the temporal bone . It most often arises as **a complication of otitis media** . The infection moves from the mucous membrane *of the mastoid process* to the bony partitions with their subsequent melting (*coalescence* = melting, hence **coalescent mastoiditis**). Rarely, the infection can spread to this location hematogenously or traumatically.

Forms

We distinguish 3 basic forms of mastoiditis:

1. **acute** (occurs 2-4 weeks after mesotitis, accounts for approximately 50% of all mastoiditis);
2. **subacute** (usually occurs as part of latent otitis media);
3. **latent** (also as part of latent otitis media).

Clinical signs

- **Acute mastoiditis** : fever , palpation soreness, retroauricular leakage, protruding pinna, purulent discharge from the ear canal, worsening of hypacus, tinnitus , osteoclastic bone destruction;
- **Subacute and latent mastoiditis** (symptoms are less pronounced): vague soreness - rather a feeling of pressure in the ear, modest exudation, profuse proliferation of granulation tissue filling the sockets, the bone reacts rather osteoplastically, the septa thicken and sclerotize.

Diagnostics

- History , **physical examination** (see symptoms);
- **Otoscopy** - the image indicates some form of *otitis media* ;
- **X-ray** (projection according to Schüller) – obscuration and disintegration of the pneumatic system;
- CT.

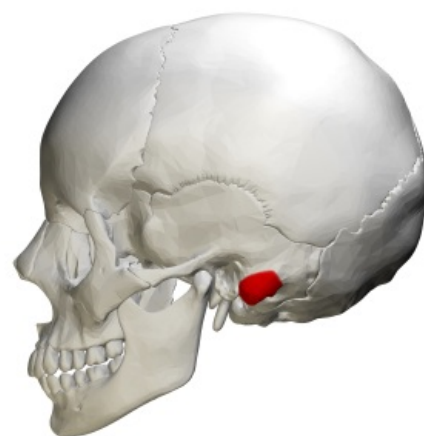


Diagram of skull bones. The mastoid process is shown in red.

Differential diagnosis

- Circumscribed external otitis with retroauricular infiltration;
- Dermatitis in the ear with subsequent retroauricular lymphadenitis;
- Palpable soreness can be caused by vertebral irritation **of the nervus occipitalis minor** .

Complications

Complications of mastoiditis arise from the possibility **of infection spreading** . It is about:

- mastoid **fistula** ;
- subperiosteal, Mouret's (under the attachment *of the digastricus muscle*) or **Bezold's** (under the attachment *of the sternocleidomastoid muscle*) abscess ;
- **thrombophlebitis** (by extension of the inflammation medially to the sphincter);
- **infectious disease of the brain** or cerebellum .

Therapy

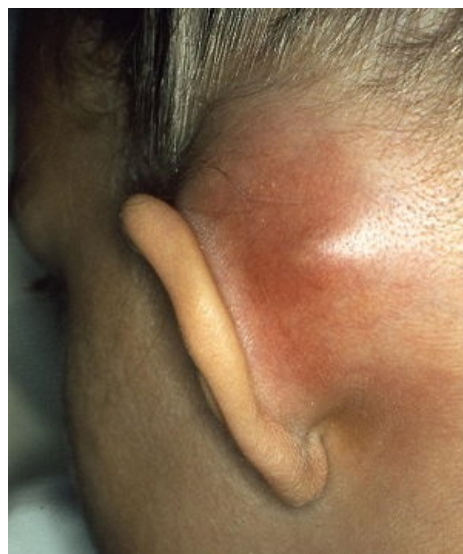- ATB ;
- **antromastoidectomy** .

Links

Source

- BENEŠ, Jiří. *Studijní materiály* [online]. ©2007. [cit. 2009]. <http://jirben2.chytrak.cz/materialy/orl_jb.doc>.

References



Subperiosteal abscess as a complication of mastoiditis

- KLOZAR, Jan, et al. *Speciální otorinolaryngologie*. 1. edition. Praha : Galén, 2005. 224 pp. ISBN 80-7262-346-X.
- VOKURKA, Martin – HUGO, Jan, et al. *Velký lékařský slovník*. 8. edition. Praha : Maxdorf, 2009. 1144 pp. ISBN 978-80-7345-166-0.
- ŠLAPÁK, Ivo, et al. *Doporučené postupy pro praktické lékaře : Bolest ucha* [online] . 1. edition. 2001. Available from <<http://www.cls.cz/dokumenty2/postupy/r078.rtf>>.