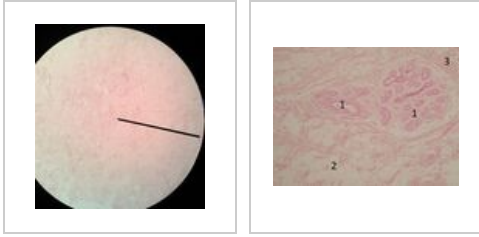


# Mamma non lactans (SFLT)

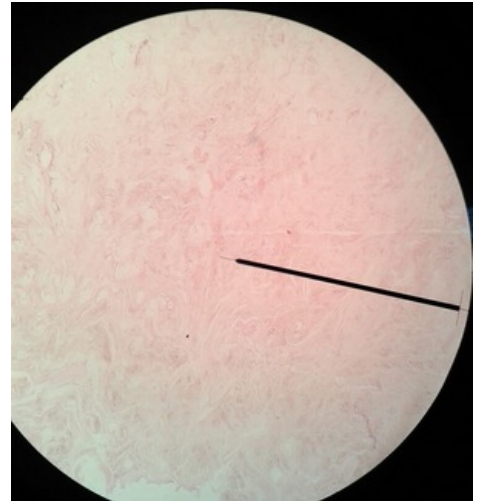


## Mamma non lactans, Preparation No. 1

In the resting mammary gland we find mainly the connective stroma, in which there are occasional clusters of tubules (ducts).

## Mamma non lactans, Preparation No. 2

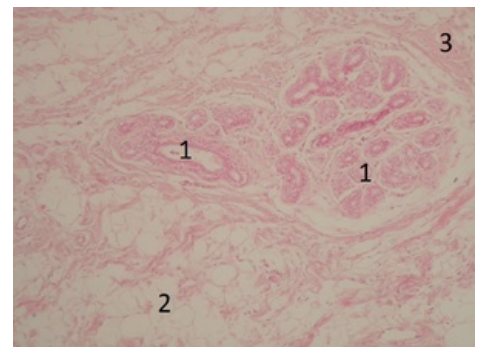
The outlets of the resting mammary gland are lined with a single-layered cuboidal epithelium.



Mamma nonlactans, connective stroma.

## Mamma non lactans, Preparation No. 3

In the resting mammary gland we find mainly connective stroma, in which there are occasional clusters of tubules (ducts) without visible secretion.



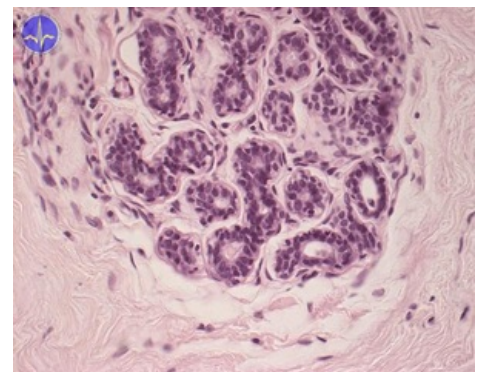
Outlets of the resting mammary gland.

## Skin System

- Mamma lactans (SFLT)
- Mamma non lactans (SFLT)

## Links

- Histological atlas (3. LF UK)



Mamma non lactans (HE)