

# Lymphatic breast drainage

The breasts contain a rich capillary network of lymphatic vessels. Drainage begins around the nipple (mamilla) and areola (areola mammae) as the areolar plexus, which is followed by the lateral continuation of the circumareolar plexus and the subareolar ventral plexus. These plexuses are connected to the regional lymph nodes of the chest and upper limbs, but also join in depth along the ductuli lactiferi and form an intraglandular lymphatic network (*note* - the mammogram may show intramammary lymph nodes if they are up to 1 centimeter in diameter, pathological).

## Regional axillary and thoracic nodes in relation of the breast

In order to describe the outflow paths, it is first necessary to recall the regional nodes of the axilla and thorax.

### Axillary nodes

A group of about 40 nodes, which are located in the fat axilla and collect lymph from the upper limb, neck, shoulder, breast and from the front and back torso (above the level of the navel). It is divided into lymphatic nodes, axillary pectorales, interpectores, subscapulares, branchiales (laterales), centrales and apicales.

#### Pectoral axillary lymph nodes

Located close to the gland and the deep area of the m. pectoralis major. The largest node, **Sorgius's**, is located at the third tooth of the m. serratus anterior. The Sorgius node is the first to be affected by a metastasis of a tumor from the upper outer quadrant of the breast. It is often swollen and causes pain on the inside of the arm when the n. intercostobrachialis is irritated.

*Tributary area* - anterior chest wall, supraumbilical abdomen and mammary.

*Outflow* - into the axillary central and infraclavicular, from there into the subclavian truncus and supraclavicular lymph nodes and then into the ductus lymphaticus dexter in the right half of the body and into the thoracic duct in the left.

#### Interpectoral axillary lymph nodes

Stored between the two pectoral muscles.

*Tributary Region* - Central part of the mammary.

*Outflow* - infra- and supraclavicular nodes.

#### Subscapular axillary lymph nodes

They are located under the m. subscapularis and m. teres major.

*Tributary area* - upper limb, scapular landscape and adjacent districts.

*Outflow* - they drain into the nodes of the axilla.

#### Brachial axillary lymph nodes

We find them laterodorsally from the brachial vein.

*Tributary region* - free upper limb.

*Outflow* - they axillary drains into the apical nodes.

#### Central axillary lymph nodes

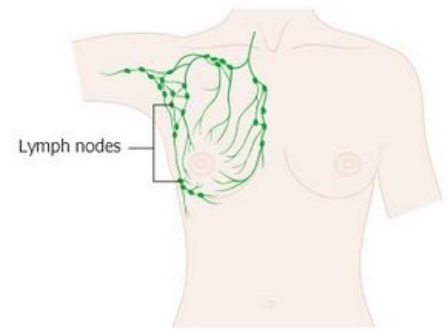
Formed in the center of the axilla above the subscapular muscle.

*Tributary region* - HK and lymphatic nodes of the brachial, subscapular and pectoral axillary.

*Outflow* - into the lymphatic nodes of the axilla.

#### Apical axillary lymph nodes

At the top of the axilla.



*Tributary region* - upper limb and all groups of axillary nodes.

*Outflow* - the subclavius truncus emerges from the nodes, which runs along the subclavian vein and opens into the thoracic duct on the left or the dexter lymphatic duct on the right. Direct outflow into the angulus venosus is possible.

### Parasternal lymph nodes

They are located on the inside of the chest along the thoracic internal veins.

*Tributary region* - medial part of mammary gland, posterior surface of anterior chest wall, anterior part of diaphragm, wall pleura, abdominal wall, upper liver

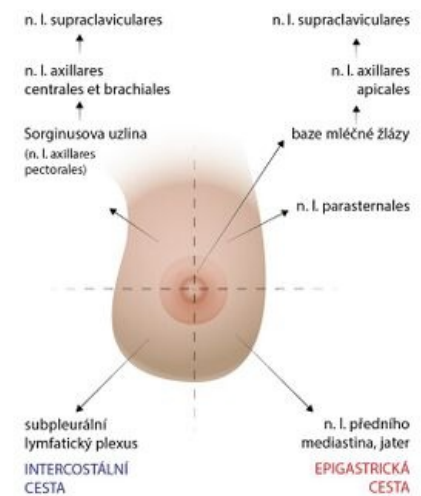*Outflow* - ductus thoracicus, ductus lymphaticus dexter; either directly or through the bronchomediastinal truncus.

## Breast quantifiers and their drainage

We divide the breast on the basis of the mammary gland into 4 quadrants  
- upper lateral, lower lateral, upper medial, lower medial (see picture)

- mammary gland bases - lymphatic collectors converge into the apical axillary lymphatic nodes and from there into the supraclavicular lymphatic nodes
- upper lateral - the main outflow path flows into the central axillary and brachial lymphatic nodes and from there into the supraclavicular lymphatic nodes. A Sorigius node is often inserted in the path.
- lower lateral - the outflow is conducted by the so-called intercostal path - it enters the subpleural lymphatic plexus.
- upper medial - lymphatic pathways run along the internal thoracic vein and end in the parasternal nerve
- lower medial- the so-called epigastric pathway - follows the superior epigastric artery and ends in the hepatic lymphatic nodes and those of the anterior mediastinum.

Lymphatic connections between the two breasts have also been repeatedly demonstrated.



Breast quadrants and their drainage

## Clinical notes

The findings of pathological anatomy show that the axillary nodes are the first to be affected during tumor spread. It is also the main direction of the spread of metastases. When the axillary nodes are affected by metastases, they are never affected at the same time. This means that side by side we find nodes affected by metastases. Due to the fact that there are lymphatic connections between the two breasts, it is always necessary to examine the bilateral breast, along with the axilla.

## Links

### related articles

- Brest
- Brest cancer
- Lymphatic tribes
- Lymphatic drainage of limbs
- Infiltrating breast cancer(preparation)

### Source

- PETROVICKÝ, Pavel, et al. Anatomy with topography and clinical applications. 1st edition. Martin: Osveta, 2001. 560 pp. Vol. 2. ISBN 80-8063-04
- ČIHÁK, Radomír. Anatomy 3rd 2nd edition. Prague: Grada Publishing, 2004. 692 pp. ISBN 978-80-247-1132-4 .

Kategorie:Anatomie Kategorie:Gynekologie Kategorie:Onkologie

- ws: Lymfatická drenáž prsu