

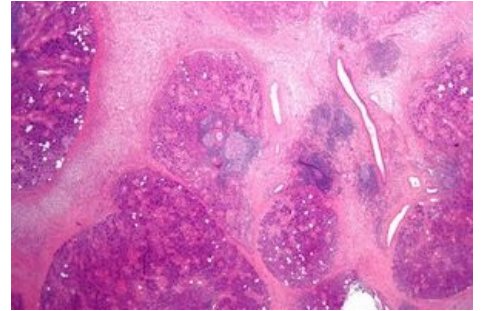
# Küttner tumor

Küttner tumour (KT) is a rare chronic inflammatory disease which affects salivary glands, usually submandibular glands. KT usually affects patients in their fifties and sixties, rarely it can appear among children. Today Küttner tumour is classified as a manifestation of Ig4 associated disease of salivary glands.

The tumor was first described by the German surgeon Hermann Küttner (1870 1932) in 1896. Because the "ü" character is foreign to many languages, the incorrect designation "Kuttner's tumor" can be found in abundance in the literature.

## Bibliography

- MELO, J. C., D. KITSKO a M. REYES-MÚGICA. Pediatric chronic sclerosing sialadenitis: Küttner tumor. *Pediatr Dev Pathol.* 2000, vol. 15, no. 2, s. 165-9, ISSN [[1] (Tel:1615-5742%7C1615-5742)].
- CULVER, E.L. a A.C. BATEMAN. General principles of IgG4-related disease. *Diag Histopatol.* 2013, vol. 19, no. 4, s. 111-118, ISSN [[2] (Tel:1756-2317%7C1756-2317)].



Microscopic image of chronic sialoadenitis