

Iliac muscle

Beginning: *fossa iliaca, crista iliaca, po linea arcuata*

Attachment: *trochanter minor*

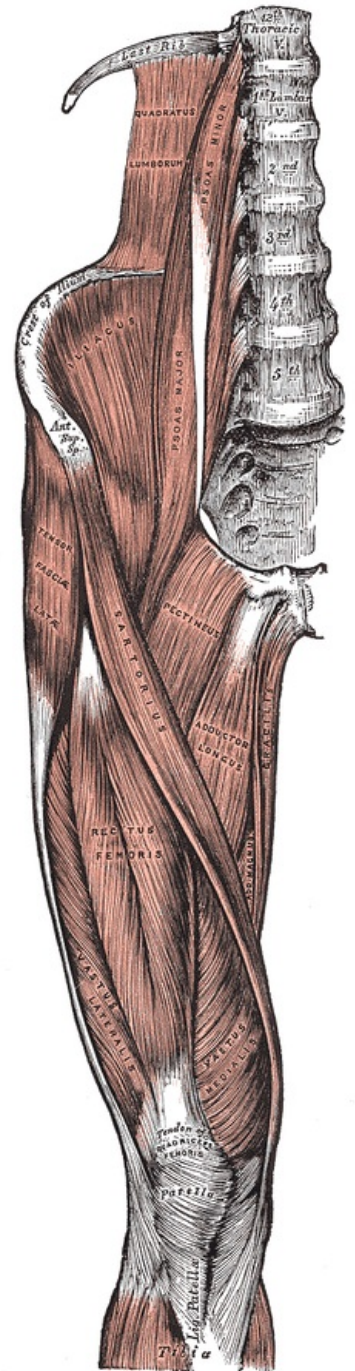
Innervation: *n. femoralis*, direct branches from *plexus lumbalis* L₁-L₃.

Functions: flexion, external rotation, auxiliary adduction at hip joint

Connects with *m. psoas major* and *m. psoas minor* to common *m. iliopsoas* which is covered by the *fascia iliaca*.

Links

- ČIHÁK, . *Anatomy 1*. 2. edition. Grada, 2001. 497 pp. ISBN 80-7169-970-5.
- VIGUÉ, Jordi. *Atlas of the Human Body*. 3. edition. Rebo, 2007. ISBN 978-80-7234-881-7.



Iliac muscle